

Use of a Valved-Conduit for Exclusion of the Infected Portion in the Prosthetic Pulmonary Valve Endocarditis

Joonho Jung, M.D., You Sun Hong, M.D., Cheol Joo Lee, M.D., Sang-Hyun Lim, M.D.,
Ho Choi, M.D., Soo-Jin Park, M.D.

A 51-year-old male was admitted to the hospital with complaints of fever and hemoptysis. After evaluation of the fever focus, he was diagnosed with pulmonary valve infective endocarditis. Thus pulmonary valve replacement and antibiotics therapy were performed and discharged. He was brought to the emergency unit presenting with a high fever ($>39^{\circ}\text{C}$) and general weakness 6 months after the initial operation. The echocardiography revealed prosthetic pulmonary valve endocarditis. Therefore, redo-pulmonary valve replacement using valved conduit was performed in the Rastelli fashion because of the risk of pulmonary arterial wall injury and recurrent endocarditis from the remnant inflammatory tissue. We report here on the successful surgical treatment of prosthetic pulmonary valve endocarditis with an alternative surgical method.

Key words: 1. Endocarditis
2. Pulmonary valve
3. Prosthetic valve endocarditis

CASE REPORT

A 51-year-old male patient with diabetes was admitted to the division of pulmonology with the chief complaints of fever and hemoptysis. A chest computed tomography scan was performed for the evaluation of persistent fever and recurrent pleural effusion, and it showed pulmonary embolism at bilateral multiple segmental arteries and segmental infarction of the involved lung segments. Based on the results, echocardiography was additionally performed and revealed isolated pulmonary valve infective endocarditis with severe pulmonary regurgitation.

After the diagnosis was made, the patient was treated with antibiotics, followed by echocardiography. The echocardiog-

raphy showed progression of pulmonary valve thickening and right heart failure. We performed pulmonary valve replacement with a #24 Sorin tissue valve. The postoperative course was uneventful and the patient was followed up at the outpatient clinic regularly with anticoagulation.

After 6 months, he was brought to the emergency unit presenting with a high fever ($>39^{\circ}\text{C}$) and general weakness that had lasted for 3 days. He was treated with antibiotics including vancomycin, imipenem, and rifampin. Methicillin-sensitive *Staphylococcus aureus* (*S. aureus*) was isolated from his blood culture, and the echocardiography showed a hypochoic movable mass on the prosthetic pulmonary valve (Fig. 1) and the pressure gradient of the prosthetic pulmonary valve was 16.2 mmHg (maximum pressure gradient)/9.4 mmHg (mean

Department of Thoracic and Cardiovascular Surgery, Ajou University School of Medicine

Received: September 24, 2012, Revised: October 19, 2012, Accepted: October 22, 2012

Corresponding author: You Sun Hong, Department of Thoracic and Cardiovascular Surgery, Ajou University School of Medicine, 206 World cup-ro, Yeongtong-gu, Suwon 443-721, Korea

(Tel) 82-31-219-5212 (Fax) 82-31-219-5215 (E-mail) yshongjin@ajou.ac.kr

© The Korean Society for Thoracic and Cardiovascular Surgery. 2013. All right reserved.

© This is an open access article distributed under the terms of the Creative Commons Attribution Non-Commercial License (<http://creativecommons.org/licenses/by-nc/3.0>) which permits unrestricted non-commercial use, distribution, and reproduction in any medium, provided the original work is properly cited.

pressure gradient). Follow-up echocardiography showed a worsened pressure gradient of the prosthetic pulmonary valve. We did a redo-pulmonary valve replacement under the impression of prosthetic valve infective endocarditis.

The prosthetic pulmonary valve leaflet was thickened with infected tissue (Fig. 2). After removal of the infected prosthetic valve, a secure portion for the new prosthetic pulmonary valve replacement was hard to find because of the risk of pulmonary vessel wall injury. Moreover, complete debridement of the remaining infected tissue seemed impossible. Thus a valved graft was made by placing a 21 mm tissue valve in the middle of a 22 mm Vascutek artificial graft (Fig.

3). After completely obliterating the proximal portion of the pulmonary arterial lumen with simple suturing for isolation of probable remnant infected debris, the valved graft was used to perform the redo-pulmonary valve replacement similar to the Rastelli operation with right ventricular outflow tract reconstruction (Fig. 4).

Immediate postoperative echocardiography showed intact prosthetic pulmonary valvular function with a peak pulmonary valve pressure gradient of 34 mmHg and a mean pulmonary valve pressure gradient of 16 mmHg. Follow-up echocardiography was performed on postoperative day #19, and the peak pulmonary valve pressure gradient was 20.71 mmHg, while the mean pulmonary valve pressure gradient was 11.14 mmHg. No more microorganisms were isolated from his blood culture. The patient is currently being treated with anti-coagulant (coumadin), presenting no respiratory or cardiovascular symptoms during follow-up in outpatient clinic for 2 years after surgery. The last echocardiography was performed at 15 months after surgery; it showed intact prosthetic valve function with a peak pulmonary valve pressure gradient of 19 mmHg and a mean pulmonary valve pressure gradient of 10 mmHg.

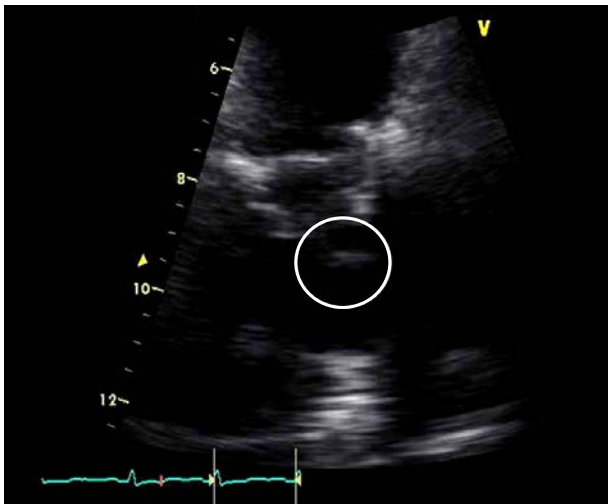

Fig. 1. The echocardiography showed a hypoechoic movable mass on the prosthetic pulmonary valve (circle).

DISCUSSION

Prosthetic valve infective endocarditis is a serious and potentially fatal complication of valve replacement. According to the data by Arvay and Lengyel [1] published in 1988, prosthetic valve endocarditis developed in 19 of 329 patients

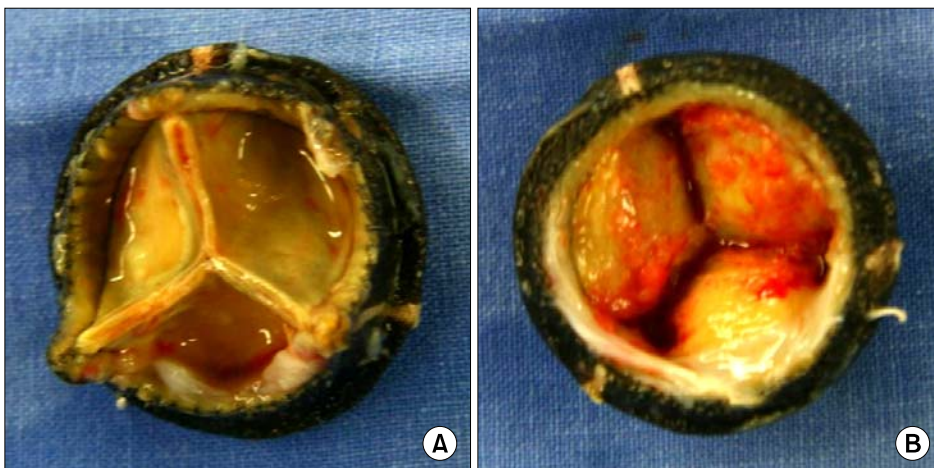

Fig. 2. (A, B) Removed prosthetic pulmonary valve. Vegetation can be seen on the valve leaflets (each side).

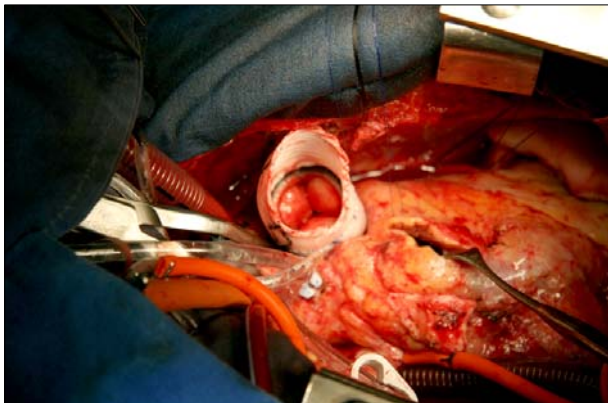


Fig. 3. The valved graft was made with a 21 mm tissue valve and 22 mm artificial graft. Before placing the valved graft, we checked for a smooth flow through it.

with bioprostheses (5.8%) and in 8 of 583 patients with mechanical valves (1.4%). The incidence of infective endocarditis that solely involves the pulmonary valve is known to be lower than that involving additional valves. Furthermore, the incidence of prosthetic pulmonary valve infective endocarditis occurring after pulmonary valve replacement is also known to be lower than that occurring after replacement of other valves. It is reported that approximately 1% of prosthetic valve endocarditis involves only the pulmonary valve and the total cases reported for isolated pulmonary valve prosthetic infective endocarditis are few in number [2]. Early prosthetic valve endocarditis and late prosthetic valve endocarditis can be classified according to the period in which prosthetic valve infective endocarditis occurs after initial valvular surgery. Early prosthetic valve endocarditis has been classified as prosthetic valve endocarditis occurring within 12 months after surgery and late prosthetic valve endocarditis as occurring later than 12 months after surgery [3]. Also, nosocomial infective endocarditis has been defined as an infection occurring >72 hours after admission to the hospital or infective endocarditis acquired in association with a significant invasive procedure performed during a recent hospitalization <8 weeks before the current hospitalization [4]. Therefore, this case can be classified early prosthetic valve endocarditis without evidence of nosocomial infection.

Although there are slight differences among published reports, *S. aureus* is found to be the most common pathogen

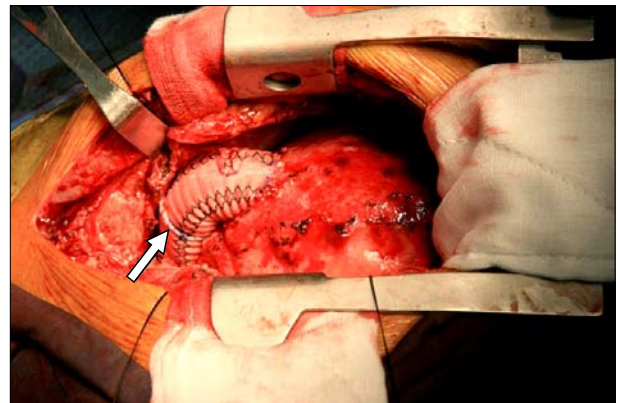


Fig. 4. After reconstruction of the right ventricular outflow tract. The stitch in the middle portion of the graft (arrow) indicates the location of the prosthetic valve.

causing native valve endocarditis, responsible for approximately 1/4 of all cases. Along with coagulase negative staphylococcus, *S. aureus* is also the most common pathogen found in prosthetic valve endocarditis [5]. In early and late prosthetic valve endocarditis, methicillin sensitive *S. aureus* is found to be a more frequent cause than methicillin-resistant *S. aureus* [5]. Prosthetic valve endocarditis caused by *S. aureus* is a fatal complication with mortality rates reaching as high as 40% [6]. The reported incidence of prosthetic valve endocarditis is about 3.1% for 12 months after surgery and 5.7% for 60 months after surgery [7]. The occurrence of cardiac complications and early valve surgery is associated with prognostic factors. However, it is reported that central nervous system complications due to embolization is not an independent risk factor [8].

This is a case report of a 51-year-old male patient with early prosthetic valve endocarditis due to methicillin-sensitive *S. aureus* who underwent a redo-pulmonary valve replacement using the complete vegetation isolation method for the prevention of recurrence of isolated prosthetic pulmonary valve infective endocarditis that had occurred six months after his initial pulmonary valve replacement with tissue valve. The infection extended to the annulus of the pulmonary valve, so we decided to anastomose to the right ventricular free wall and distal portion of the pulmonary artery, which were not infected, rather than the annulus or proximal portion of the pulmonary artery. However, we could not preserve the annu-

lus of the pulmonary valve, so we needed a vascular conduit for prosthetic valve implantation. After the surgery, we managed follow-up taking into consideration that the artificial graft could have become a re-infection source in the future, so the patient was treated with multiple antibiotics for 12 weeks, postoperative echocardiography 3 times, and repeated blood culture even though he did not have a fever. The patient received effective and successful surgical treatment and was discharged without any significant symptoms or complications.

This case suggests that when complete removal of vegetation is difficult either structurally or technically, more diverse surgical techniques should be considered for the prevention of recurrence of infective endocarditis by the remnant vegetation. The limitation of this report is that no such surgery of the same method has been reported, so this method has not yet been proven to be generalizable. Also, a lack of long-term follow-up data on the surgery could be another limitation.

CONFLICT OF INTEREST

No potential conflict of interest relevant to this article was reported.

REFERENCES

1. Arvay A, Lengyel M. *Incidence and risk factors of prosthetic valve endocarditis*. Eur J Cardiothorac Surg 1988;2: 340-6.
2. Hill EE, Herregods MC, Vanderschueren S, Claus P, Peetermans WE, Herijgers P. *Management of prosthetic valve infective endocarditis*. Am J Cardiol 2008;101:1174-8.
3. Horstkotte D, Follath F, Gutschik E, et al. *Guidelines on prevention, diagnosis and treatment of infective endocarditis: executive summary*. Rev Esp Cardiol 2004;57:952-62.
4. Mouly S, Ruimy R, Launay O, et al. *The changing clinical aspects of infective endocarditis: descriptive review of 90 episodes in a French teaching hospital and risk factors for death*. J Infect 2002;45:246-56.
5. Manne MB, Shrestha NK, Lytle BW, et al. *Outcomes after surgical treatment of native and prosthetic valve infective endocarditis*. Ann Thorac Surg 2012;93:489-93.
6. Chirouze C, Cabell CH, Fowler VG Jr, et al. *Prognostic factors in 61 cases of Staphylococcus aureus prosthetic valve infective endocarditis from the International Collaboration on Endocarditis merged database*. Clin Infect Dis 2004;38: 1323-7.
7. Calderwood SB, Swinski LA, Waternaux CM, Karchmer AW, Buckley MJ. *Risk factors for the development of prosthetic valve endocarditis*. Circulation 1985;72:31-7.
8. John MD, Hibberd PL, Karchmer AW, Sleeper LA, Calderwood SB. *Staphylococcus aureus prosthetic valve endocarditis: optimal management and risk factors for death*. Clin Infect Dis 1998;26:1302-9.