

# Preoperative thrombocytosis predicts prognosis in stage II colorectal cancer patients

Yong Sun Lee, Kwang Wook Suh, Seung Yeop Oh

Department of Surgery, Ajou University School of Medicine, Suwon, Korea

**Purpose:** Thrombocytosis is known to be a poor prognostic factor in several types of solid tumors. The prognostic role of preoperative thrombocytosis in colorectal cancer remains limited. The aim of this study is to investigate the prognostic role of preoperative thrombocytosis in stage II colorectal cancer.

**Methods:** Two hundred eighty-four patients with stage II colorectal cancer who underwent surgical resection between December 2003 and December 2009 were retrospectively reviewed. Thrombocytosis was defined as platelet  $> 450 \times 10^9/L$ . We compared patients with thrombocytosis and those without thrombocytosis in terms of survival.

**Results:** The 5-year disease-free survival (DFS) rates were lower in patients with thrombocytosis compared to those without thrombocytosis in stage II colorectal cancer (73.3% vs. 89.6%,  $P = 0.021$ ). Cox multivariate analysis demonstrated that thrombocytosis (hazard ratio, 2.945; 95% confidence interval, 1.127–7.697;  $P = 0.028$ ) was independently associated with DFS in patients with stage II colorectal cancer.

**Conclusion:** This study showed that thrombocytosis is a prognostic factor predicting DFS in stage II colorectal cancer patients.

[Ann Surg Treat Res 2016;90(6):322-327]

**Key Words:** Thrombocytosis, Prognosis, Colorectal neoplasms

## INTRODUCTION

Colorectal cancer (CRC) remains a leading cause of cancer related death worldwide. A consistent fraction of patients will relapse, mostly within the first 3 years. There is clear evidence that 5-fluorouracil (5-FU)-based adjuvant chemotherapy has a beneficial effect on tumor relapse and overall survival in patients with a curative resected stage III colon cancer [1]. On the contrary, the benefit of adjuvant treatment is still debatable in stage II colon cancer [2]. Prognostic markers have been investigated to establish which stage II patients will suffer from recurrences and which could benefit from adjuvant treatment. Currently, several histopathologic factors associated with poor outcomes in stage II CRC include the depth of transmural tumor invasion, tumor differentiation, the presence of lymphovascular

and perineural invasion, and the pattern of growth at the edge of the tumor [3-6].

Thrombocytosis has been identified as an adverse prognostic indicator in lung cancer [7], esophageal cancer [8], renal cell carcinoma [9], and gynecological malignancies [10,11], and breast cancer [12].

In case of CRC, there are some studies showing an inverse correlation between the survival of CRC patients and preoperative platelet count levels [13-15].

In this study, we investigated the impact of preoperative thrombocytosis on prognosis for patients with stage II CRC.

## METHODS

The medical records of 330 consecutive patients who con-

Received February 3, 2016, Reviewed March 14, 2016,  
Accepted March 14, 2016

Corresponding Author: Seung Yeop Oh

Department of Surgery, Ajou University School of Medicine, 206 World  
cup-ro, Yeongtong-gu, Suwon 16499, Korea

Tel: +82-31-219-4450, Fax: +82-31-219-5755

E-mail: kgsosy@aumc.ac.kr

Copyright © 2016, the Korean Surgical Society

© Annals of Surgical Treatment and Research is an Open Access Journal. All articles are distributed under the terms of the Creative Commons Attribution Non-Commercial License (<http://creativecommons.org/licenses/by-nc/4.0/>) which permits unrestricted non-commercial use, distribution, and reproduction in any medium, provided the original work is properly cited.

firmed to be stage II after curative surgical resection for CRCs at our hospital between December 2003 and December 2009 were retrospectively reviewed. We excluded patients who received preoperative chemoradiation therapy (n = 18), or had a history of other primary cancer (n = 28). The data that were analyzed included age at diagnosis, gender, primary tumor site, tumor T stage, and histological grade and preoperative platelet count. Staging was performed according to the TNM classification of the American Joint Committee on Cancer (7th edition, 2002). The study was approved by the Institutional Review Board at Ajou University School of Medicine.

Preoperative blood samples were obtained from patients with CRC within 2 weeks prior to operation. Thrombocytosis was defined as a pretreatment platelet count  $> 450 \times 10^9/L$  without known inflammatory conditions.

Regimens of chemotherapy were capecitabine or infusional 5-FU/leucovorin (LV), UFT, Doxifluridine, and 5-fluorouracil/leucovorin/oxaliplatin (FOLFOX). We recommended adjuvant chemotherapy with Xeloda, infusional 5-FU/LV, and FOLFOX after complete surgical resection in stage II CRC patients with poorly differentiated tumor, T4 lesion, lymphovascular invasion, and perineural invasion. Patients without these features were recommended to receive UFT or Doxifluridine. Capecitabine was scheduled to be administered orally twice daily on days 1–14 every 3 weeks to 8 cycles. Infusional 5-FU ( $800 \text{ mg/m}^2$ ) plus bolus injection of 30 mg of LV were planned to be administered for 5 consecutive days to six cycles. FOLFOX chemotherapy was planned to be administered to 12 cycles during a 6-month period. The patients received a 2-hour infusion of oxaliplatin ( $85 \text{ mg/m}^2$  on day 1, in addition to the standard LV/5-FU2 regimen (FOLFOX4). The UFT or Doxifluridine was given daily and intended to continue for 1 year. Planned schedule was stopped in case of disease relapse, patient refusal, or intolerable toxicity.

Median follow-up period were 92 months (range: 3–131 months). Disease-free survival and cancer-specific survival (CSS) is calculated for all patients from the date of surgery until recurrence and death from CRC.

Pearson chi-square or Fisher exact test was used to assess differences in the clinicopathological features. Continuous data were compared by Student t-test. Kaplan-Meier survival analysis with the log-rank test was used to evaluate the prognosis for CRC. Univariate comparisons between survival curves for each variable were performed by using the log-rank test. Variables with a P-value  $< 0.30$  were entered into a multivariate analysis. Multivariate analysis was performed using the Cox regression model with a stepwise forward method to derive a final model of the variables. Data were analyzed using SPSS ver. 13.0 (SPSS Inc., Chicago, IL, USA).

## RESULTS

### Clinicopathological characteristics

Table 1 shows the characteristics of patients who underwent curative resection for stage II CRC from 2003 to 2009. The 284 patients included 166 men and 118 women with a median age of 65 years (range, 27–87 years). Twenty of the patients (7%) had a thrombocytosis. There was no significant difference between patients showing thrombocytosis and those without thrombocytosis with respect to age, tumor differentiation, the depth of invasion, lymphatic invasion, venous invasion and

**Table 1.** Clinicopathological characteristics of patients (n = 284)

Variable	No. (%)
Sex	
Male	166 (58.5)
Female	118 (41.5)
Median age (yr)	65
Location	
Colon	177 (62.3)
Rectum	107 (37.7)
Tumor differentiation	
Well	38 (13.4)
Moderate	218 (76.8)
Poor	28 (9.9)
Tumor size (cm)	
$\leq 5$	118 (41.5)
$> 5$	166 (58.5)
Depth of invasion	
T3	261 (91.9)
T4	23 (8.1)
Lymphatic invasion	
Positive	198 (69.7)
Negative	86 (30.3)
Venous invasion	
Positive	250 (88.0)
Negative	34 (12.0)
Perineural invasion	
Positive	264 (93.0)
Negative	20 (7.0)
Adjuvant chemotherapy	
Completion	122 (43.0)
Incompletion	135 (47.5)
No	27 (9.5)
Chemotherapy regimen	
Xeloda	40 (14.1)
Infusional 5-FU/LV	18 (6.3)
FOLFOX	3 (1.1)
Other oral 5-FU	196 (69.0)
Platelet count ( $\times 10^9/L$ )	
$< 450$	264 (93.0)
$\geq 450$	20 (7.0)

5-FU/LV, 5-fluorouracil/leucovorin; FOLFOX, 5-fluorouracil/leucovorin/oxaliplatin.

perineural invasion, completion of adjuvant chemotherapy. However, sex ( $P = 0.007$ ), tumor location ( $P = 0.008$ ), and tumor size ( $P = 0.043$ ) were significantly different between the 2 groups. Two hundred fifty-seven patients received adjuvant chemotherapy, 237 in patient without thrombocytosis, and 20 in patient with thrombocytosis. Among patients without thrombocytosis, 112 patients (42.4%) completed full cycles of treatment, 125 patients (47.3%) could not complete. Among patients with thrombocytosis, 10 patients (50.0%) completed full cycles of treatment, the rest (50.0%) could not complete (Table 2).

Median follow-up was 98.0 months (range, 16–126 months)

**Table 2.** Clinicopathological characteristics of patients

Variable	Platelets <450 (n = 264)	Platelets $\geq$ 450 (n = 20)	P-value
Sex			0.007
Male	160 (60.6)	6 (30.0)	
Female	104 (39.4)	14 (70.0)	
Median age (yr)	65.0	63.5	
Location			0.008
Colon	159 (60.2)	18 (90.0)	
Rectum	105 (39.8)	2 (10.0)	
Tumor differentiation			>0.999
Well	35 (13.3)	3 (15.0)	
Moderate	203 (76.9)	15 (75.0)	
Poor	26 (9.8)	2 (10.0)	
Tumor size (cm)			0.043
$\leq$ 5	114 (43.2)	4 (20.0)	
>5	150 (56.8)	16 (80.0)	
Depth of invasion			>0.999
T3	243 (92.0)	18 (90.0)	
T4	21 (8.0)	2 (10.0)	
Lymphatic invasion			0.594
Positive	183 (69.3)	15 (75.0)	
Negative	81 (30.7)	5 (25.0)	
Venous invasion			0.146
Positive	230 (87.1)	20 (100)	
Negative	34 (12.9)	0 (0)	
Perineural invasion			>0.999
Positive	245 (92.8)	19 (95.0)	
Negative	19 (7.2)	1 (5.0)	
Adjuvant chemotherapy			0.313
Completion	112 (42.4)	10 (50.0)	
Incompletion	125 (47.3)	10 (50.0)	
No	27 (10.2)	0 (0)	
Chemotherapy regimen			0.314
None	27 (10.2)	0 (0)	
Xeloda	35 (13.3)	5 (25.0)	
Infusional 5-FU/LV	16 (6.1)	2 (10.0)	
FOLFOX	3 (1.1)	0 (0)	
Other oral 5-FU	183 (69.3)	13 (65.0)	

Values are presented as number (%).

5-FU/LV, 5-fluorouracil/leucovorin; FOLFOX, 5-fluorouracil/leucovorin/oxaliplatin.

in patients with thrombocytosis and 92.0 months (range, 3–131 months) in those without thrombocytosis.

### Survival analysis

The 5-year disease-free survival rates were lower in patients with thrombocytosis compared to those without thrombocytosis in stage II CRC (73.3% vs. 89.6%,  $P = 0.021$ ) (Table 3). Cox multivariate analysis demonstrated that thrombocytosis (hazard ratio, 2.945; 95% confidence interval, 1.127–7.697;  $P = 0.028$ ) was independently associated with disease-free survival in patients with stage II CRC (Table 4) (Fig. 1). The 5-year CSS rates were also lower in patients with thrombocytosis compared to those without thrombocytosis (85.0% vs. 95.2%,  $P = 0.046$ ), but it was not an independent prognostic factor in multivariate

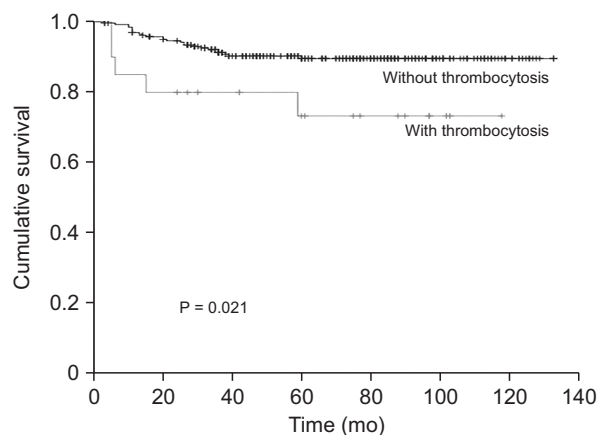
**Table 3.** Univariate analysis of survival according to thrombocytosis

Variable	No.	5-year DFS	P-value	5-year OS	P-value
Sex			0.344		0.889
Male	166	86.4		94.3	
Female	118	90.9		94.8	
Age (yr)			0.702		0.227
<65	149	89.2		96.5	
$\geq$ 65	135	87.2		93.1	
Location			0.318		0.696
Colon	177	90.2		94.1	
Rectum	107	85.2		95.1	
Tumor differentiation			0.999		0.598
Well	38	89.1		91.7	
Moderate	218	88.0		95.2	
Poor	28	89.0		92.4	
Tumor size (cm)			0.493		0.966
$\leq$ 5	118	87.1		94.6	
>5	166	89.1		94.5	
Depth of invasion			0.069		0.456
T3	261	89.3		94.8	
T4	23	77.8		90.9	
Lymphatic invasion			0.659		0.780
Negative	198	89.2		94.7	
Positive	86	86.1		94.0	
Venous invasion			0.823		0.870
Negative	250	88.4		94.6	
Positive	34	87.7		93.9	
Perineural invasion			0.175		0.332
Negative	264	89.2		94.9	
Positive	20	76.5		89.7	
Adjuvant chemotherapy			0.133		0.143
No	27	77.1		87.5	
Incompletion	133	92.3		96.8	
Completion	124	85.8		93.5	
Platelet count ( $\times 10^9/L$ )			0.021		0.046
<450	264	89.6		95.2	
$\geq$ 450	20	73.3		85.0	

**Table 4.** Multivariate analysis for disease-free survival in patients with stage II colorectal cancers

Platelet count ( $\times 10^9/L$ )	HR (95% CI)	P-value
<450	1	-
$\geq 450$	2.945 (1.127–7.697)	0.028

HR, hazard ratio; CI, confidence interval.

**Fig. 1.** Comparison of 5-year disease-free survival rate between patients with thrombocytosis and those without thrombocytosis.

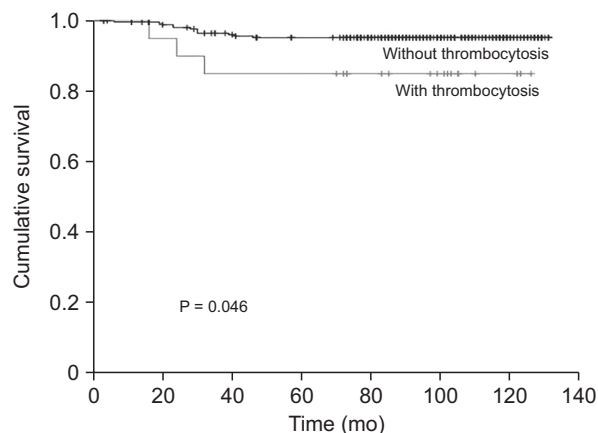
analysis (Fig. 2).

## DISCUSSION

Thrombocytosis has been reported to be associated with poor prognosis in a variety of solid tumours, including gynaecological [16], lung [7], renal [9], esophageal [8], and breast malignancies [12]. Association between thrombocytosis and CRC was also investigated by several studies. The majority of the studies demonstrate that thrombocytosis is a prognostic indicator for outcome [13-15], while one study suggests that it has no prognostic value [17]. However, the prognostic role of thrombocytosis in CRC remains determined because the inclusion criteria are different and definition of thrombocytosis differs.

We found that patients with thrombocytosis show decreased disease free survival in stage II CRC. In multivariate analysis, thrombocytosis is associated with poor prognosis in stage II rectal cancer. Stage II CRC was classified into T3 and T4 cancer according to the depth of invasion. This study suggests thrombocytosis may be a more powerful prognostic factor in stage II CRC although the definition of thrombocytosis is various between studies.

The definition of thrombocytosis in patients with CRC was used differently by previous studies. We analyzed survival analysis using different definition to get a significant difference

**Fig. 2.** Comparison of 5-year cancer-specific survival rate between patients with thrombocytosis and those without thrombocytosis.

in stage II CRC. According to the results of the analysis, thrombocytosis was defined as higher than  $450 \times 10^9/L$  in this study. As a result, the incidence of thrombocytosis was lower in our studies compared to previous studies, although the sample size is much larger than previous studies.

There are several reports that demonstrated the association of thrombocytosis with survival in CRC [13-15,18]. On the contrary, Nyasavajjala et al. [17] asserted that preoperative thrombocytosis is not a prognostic factor for CRC. They asserted the previous result to the small number of cases.

Sasaki et al. [15] investigated association of thrombocytosis with survival of 636 patients with CRC. They reported that the preoperative thrombocytosis is a potential predictive factor of poor survival and high recurrence rate in patients with CRC. They explained the difference from the previous study was due to the different definition of thrombocytosis and the length of the follow-up period.

Many abnormalities of the coagulation system have been reported to be associated with cancer progression and prognosis. Among them, the *in vivo* depletion of platelets markedly reduced experimental metastasis, and the formation of platelet aggregates around tumor cells has been shown to inhibit the *in vitro* tumor lysing activity of natural killer cells.

We hypothesized that the prognostic significance may be different according to the stage. Kandemir et al. [18] suggested that thrombocytosis is strongly associated with poor survival in patients with node-negative colon cancer, which indicate that abnormal thrombocytosis strongly correlates with local cancer progression of the primary tumor, but not with distant metastasis.

Sasaki et al. [15] analyzed the association between preoperative thrombocytosis and survival according to the stage. They reported that preoperative thrombocytosis was a prognostic factor in CSS in patients at stage II and in disease-free survival

in patients at stages II and III. They showed that the most evident prognostic significance of thrombocytosis for both CSS and DFS could be observed in stage III cases.

Our study showed that the preoperative thrombocytosis was a significant prognostic factor for survival in patients with stage II CRC.

Adjuvant chemotherapy is the standard of treatment for stage III colon cancer. Regarding stage II disease, it is recommended for patients with high-risk factors, including T4 tumor, lymphovascular invasion, and poorly differentiated tumor. In this study, adjuvant chemotherapy was performed in patients with high-risk factors. This is why these factors were not prognostic factors in this study. However, preoperative thrombocytosis was a prognostic factor in stage II CRC in multivariate analysis. Preoperative thrombocytosis should be considered in the decision of adjuvant chemotherapy in stage II CRC. All patients with thrombocytosis underwent chemotherapy, but most of them received oral chemotherapy and did not complete the intended schedule. In this study, it is difficult to evaluate the impact of chemotherapy because the

chemotherapy regimens are various, most of them are oral regimens, and chemotherapy is incomplete.

Our study has a few limitations. First, the number of patients is small to provide enough power to draw any definitive conclusions regarding oncologic outcomes. Second, a single-institution retrospective analysis has inherent selection bias. Third, the definition of thrombocytosis should be discussed in the future.

In conclusion, this study showed that thrombocytosis is a prognostic factor predicting DFS in stage II CRC patients, although the cutoff of thrombocytosis needs to be discussed. And further studies using a larger sample size are warranted to establish the role of thrombocytosis in stage II CRC more precisely.

## CONFLICTS OF INTEREST

No potential conflict of interest relevant to this article was reported.

## REFERENCES

- O'Connell MJ, Mailliard JA, Kahn MJ, Macdonald JS, Haller DG, Mayer RJ, et al. Controlled trial of fluorouracil and low-dose leucovorin given for 6 months as postoperative adjuvant therapy for colon cancer. *J Clin Oncol* 1997;15:246-50.
- Zaniboni A, Labianca R; Gruppo Italiano per lo Studio e la Cura dei Tumori del Digerente. Adjuvant therapy for stage II colon cancer: an elephant in the living room? *Ann Oncol* 2004;15:1310-8.
- Griffin MR, Bergstralh EJ, Coffey RJ, Beart RW Jr, Melton LJ 3rd. Predictors of survival after curative resection of carcinoma of the colon and rectum. *Cancer* 1987;60:2318-24.
- Wiggers T, Arends JW, Volovics A. Regression analysis of prognostic factors in colorectal cancer after curative resections. *Dis Colon Rectum* 1988;31:33-41.
- Minsky BD, Mies C, Rich TA, Recht A. Lymphatic vessel invasion is an independent prognostic factor for survival in colorectal cancer. *Int J Radiat Oncol Biol Phys* 1989;17:311-8.
- Betge J, Pollheimer MJ, Lindtner RA, Kornprat P, Schlemmer A, Rehak P, et al. Intramural and extramural vascular invasion in colorectal cancer: prognostic significance and quality of pathology reporting. *Cancer* 2012;118:628-38.
- Maraz A, Furak J, Varga Z, Kahan Z, Tiszlavicz L, Hideghety K. Thrombocytosis has a negative prognostic value in lung cancer. *Anticancer Res* 2013;33:1725-9.
- Shimada H, Oohira G, Okazumi S, Matsuura H, Nabeya Y, Hayashi H, et al. Thrombocytosis associated with poor prognosis in patients with esophageal carcinoma. *J Am Coll Surg* 2004;198:737-41.
- Men H, Liang C, Yu M. Thrombocytosis as a prognostic factor in patients with renal cell carcinoma: a meta-analysis of literature. *J Cancer Res Ther* 2015;11:67-72.
- Lerner DL, Walsh CS, Cass I, Karlan BY, Li AJ. The prognostic significance of thrombocytosis in uterine papillary serous carcinomas. *Gynecol Oncol* 2007;104:91-4.
- Stone RL, Nick AM, McNeish IA, Balkwill F, Han HD, Bottsford-Miller J, et al. Paraneoplastic thrombocytosis in ovarian cancer. *N Engl J Med* 2012;366:610-8.
- Taucher S, Salat A, Gnant M, Kwasny W, Mlineritsch B, Menzel RC, et al. Impact of pretreatment thrombocytosis on survival in primary breast cancer. *Thromb Haemost* 2003;89:1098-106.
- Qiu MZ, Yuan ZY, Luo HY, Ruan DY, Wang ZQ, Wang FH, et al. Impact of pretreatment hematologic profile on survival of colorectal cancer patients. *Tumour Biol* 2010;31:255-60.
- Ishizuka M, Nagata H, Takagi K, Iwasaki Y, Kubota K. Preoperative thrombocytosis is associated with survival after surgery for colorectal cancer. *J Surg Oncol* 2012;106:887-91.
- Sasaki K, Kawai K, Tsuno NH, Sunami E, Kitayama J. Impact of preoperative thrombocytosis on the survival of patients with primary colorectal cancer. *World J Surg* 2012;36:192-200.
- Scholz HS, Petru E, Gücer F, Haas J, Tamussino K, Winter R. Preoperative

thrombocytosis is an independent prognostic factor in stage III and IV endometrial cancer. *Anticancer Res* 2000;20(5C):3983-5.

17. Nyasavajjala SM, Runau F, Datta S,

Annette H, Shaw AG, Lund JN. Is there a role for pre-operative thrombocytosis in the management of colorectal cancer? *Int J Surg* 2010;8:436-8.

18. Kandemir EG, Mayadagli A, Karagoz B,

Bilgi O, Turken O, Yaylaci M. Prognostic significance of thrombocytosis in node-negative colon cancer. *J Int Med Res* 2005;33:228-35.