

# Comparison of the Pentax AirwayScope and McGrath MAC videolaryngoscope for endotracheal intubation in patients with a normal airway

Jiyoung Lee, MD<sup>a</sup>, Hyun Jeong Kwak, MD<sup>b</sup>, Ji Yeon Lee, MD<sup>b</sup>, Min Young Chang, MD<sup>c</sup>, Sook Young Lee, MD<sup>c</sup>, Jong Yeop Kim, MD<sup>c,\*</sup>

## Abstract

Various videolaryngoscopes (VLs) have been developed to provide a better laryngeal view and facilitate difficult intubations. The goal of this study was to compare 2 VLs, the Pentax AWS and the McGrath VL, with respect to intubation time and ease of intubation.

One hundred forty patients aged 19 to 65 years (American Society of Anesthesiologists classification I or II), who required tracheal intubation for elective surgery, were randomly assigned to 1 of the 2 groups: the Pentax AWS (n = 70) or the McGrath VL (n = 70). The primary outcome was time to intubation (TTI) measured by a blind observer. The intubation difficulty scale (IDS), percentage of glottic opening (POGO) scale, glottic grade, use of optimal external laryngeal manipulation (OELM), and ease of intubation were also recorded.

The Pentax AWS provided a better laryngeal view than the McGrath VL with respect to the Cormack-Lehane (CL) glottic grade (1/2a/2b) (63/7/0 vs 43/24/3,  $P < .001$ ) and the POGO scale (median [interquartile range, IQR]) (100 [100–100] vs 100 [80–100],  $P < .001$ ). The IDS was significantly lower in the Pentax AWS group compared with the McGrath VL group (median [IQR]) (0 [0–0] vs 0 [0–1],  $P < .001$ ). However, the TTI was similar in both the Pentax AWS and McGrath VL groups (median [IQR]) (30 [27–34] vs 32 [27–35] seconds,  $P = .440$ ). OELM and ease of intubation were also similar between the 2 groups.

The Pentax AWS offered a superior laryngeal view compared with the McGrath VL. There was no significant difference in either the intubation time or ease of intubation using these 2 devices in patients with normal airways.

**Abbreviations:** ASA = American Society of Anesthesiologists, AWS = AirwayScope, BIS = bispectral index, ETT = endotracheal tube, IDS = intubation difficulty scale, TTI = time to intubation, VL = videolaryngoscope.

**Keywords:** anesthetic technique, McGrath Videolaryngoscope, Pentax AirwayScope

## 1. Introduction

Videolaryngoscopes (VLs) were created by combining features of classic laryngoscopes and fiber-optic bronchoscopes. VLs facilitate tracheal intubation by providing a superior view of the larynx without aligning the oral-pharyngeal-laryngeal axes.<sup>[1–4]</sup> VLs also decrease the incidence of intubation difficulties, increase the overall success rate of intubation,<sup>[2,5]</sup> and facilitate the training of inexperienced practitioners.<sup>[6]</sup>

The Pentax AirwayScope (AWS) (Pentax, Tokyo, Japan) consists of a disposable polycarbonate blade, a liquid crystal

display (LCD) monitor, and an image tube with a camera. The blade of the Pentax AWS has 2 channels for the insertion of an endotracheal tube (ETT) and a suction catheter,<sup>[7]</sup> and its curved shape conforms to the anatomy of the upper airway. After inserting the blade into the patient's mouth and aligning the target signal on the screen with the glottic opening, an ETT can be directed through the vocal cords without additional handling.<sup>[8]</sup> The McGrath VL (Aircraft Medical, Covidien LLC, Mansfield, MA) is a portable device with an angulated single-use blade of adjustable size and an LCD monitor mounted on top of the handle.

Both the Pentax AWS and the McGrath VL offer a better laryngeal view and are helpful in managing difficult airways<sup>[2,5,9,10]</sup>; however, better visualization of the larynx does not always guarantee successful intubation or a shorter intubation time.<sup>[3,11,12]</sup> A prior study using manikins with normal airway models demonstrated a shorter intubation time with the Pentax AWS compared with the McGrath VL.<sup>[13]</sup> To date, however, no clinical study has directly compared the Pentax AWS with the McGrath VL in patients with normal airways. Therefore, we conducted a prospective, randomized trial that compared the Pentax AWS and the McGrath VL with respect to laryngeal view, intubation time, and ease of intubation in adult patients with normal airways.

## 2. Methods

This study was approved by the institutional review board of Ajou University Hospital, Suwon, Korea (AJIRB-DEV-OBS-16-473) and registered at ClinicalTrials.gov (NCT 02997488). We

Editor: Abdelouahab Bellou.

The authors declare no funding and conflicts of interest.

<sup>a</sup> Department of Anesthesiology and Pain Medicine, CHA Bundang Medical Center, CHA University, Seongnam, <sup>b</sup> Department of Anesthesiology and Pain Medicine, Gachon University, Gil Medical Center, Incheon, <sup>c</sup> Department of Anesthesiology and Pain Medicine, Ajou University School of Medicine, Suwon, Korea.

\* Correspondence: Jong Yeop Kim, Department of Anesthesiology and Pain Medicine, Ajou University School of Medicine, San 5-1, Wonchon-dong, Yeongtong-gu, Suwon 16499, Korea (e-mail: kjiyeop@ajou.ac.kr).

Copyright © 2017 the Author(s). Published by Wolters Kluwer Health, Inc. This is an open access article distributed under the terms of the Creative Commons Attribution-Non Commercial License 4.0 (CCBY-NC), where it is permissible to download, share, remix, transform, and buildup the work provided it is properly cited. The work cannot be used commercially without permission from the journal.

Medicine (2017) 96:46(e8713)

Received: 26 July 2017 / Received in final form: 10 October 2017 / Accepted: 26 October 2017

<http://dx.doi.org/10.1097/MD.00000000000008713>

obtained written informed consent from all patients involved in this study. We prospectively recruited 140 patients between the ages of 19 and 65, American Society of Anesthesiologists physical status I or II, who were scheduled for elective surgery requiring orotracheal intubation. The patients' weight, height, Mallampati score, inter-incisor distance with maximal mouth opening, thyromental distance, cervical spine mobility (normal, reduced, or fixed), and upper incisor status (normal, absent, or prominent) were assessed preoperatively. Patients were excluded from this study if there was a suspected difficult airway (Mallampati score 4), known cervical spine injury, the need for rapid sequence induction, morbid obesity (body mass index  $>40\text{ kg/m}^2$ ), or the need for emergency surgery. Ultimately, 140 patients qualified for this study and were randomly assigned to either the Pentax AWS or McGrath VL group; randomization (1:1) was based on a computer-generated random numbers table.

Patients did not receive premedication prior to surgery. In the operating room, standard monitoring was used for all patients, including pulse oximetry, electrocardiography, noninvasive blood pressure monitoring, and the bispectral index (BIS) with a BIS Quattro sensor (Covidien LLC). Three minutes after preoxygenation, we induced anesthesia with fentanyl 0.5 to 1.5  $\mu\text{g/kg}$ , propofol 1.5 to 2.0  $\text{mg/kg}$ , and rocuronium 0.6 to 1.0  $\text{mg/kg}$ . After induction of anesthesia, the patients' lungs were ventilated with 100% oxygen. About 2 minutes after rocuronium injection, orotracheal intubation was performed with adequate neuromuscular blockade. Patients were intubated by 1 of the 2 anesthesiologists, both of whom had  $>10$  years of clinical experience and had performed at least 20 successful intubations using both VL devices. The vocal cords and ETT insertions were visualized using the monitor of the Pentax AWS or the McGrath VL; ETTs with an inner diameter of 7.0 mm were used for both male and female patients. Approximately  $60^\circ$  angulated stylets (Mallinckrodt intubating stylet, Covidien, Ireland) were used as per the manufacturer's recommendation for the McGrath VL group. The primary outcome variable was time to intubation (TTI), defined as the time from inserting the blade between the patient's incisors to the first appearance of end-tidal carbon dioxide on the capnograph. An observer who was blinded to the patient group continuously watched a monitor to measure the TTI; another investigator performed optimal external laryngeal manipulation (OELM) to facilitate intubation if requested. If the intubation attempt took longer than 60 seconds or the patient's oxygen saturation ( $\text{SpO}_2$ ) dropped below 95%, a different method of intubation would be performed following mask ventilation and the VL intubation would be deemed a failure. The operator recorded the Cormack-Lehane (CL) glottic view classification,<sup>[14]</sup> percentage of glottic opening (POGO) scale,<sup>[15]</sup> intubation difficulty scale (IDS),<sup>[16]</sup> and the ease of intubation (5-point numerical rating scale). The operator also noted oropharyngeal bleeding if the VL blade was blood-tinged or if the patient showed signs of mucosal bleeding; bleeding was graded as none, trace, moderate, or severe. Patients were evaluated for sore throat and hoarseness in the post-anesthesia care unit (PACU). Mean arterial pressure, heart rate,  $\text{SpO}_2$ , and BIS were recorded before induction of anesthesia, 1 minute after induction, before intubation, and 1 minute after intubation.

### 2.1. Statistical analysis

To estimate the sample size, we used the mean TTI and standard deviation (SD) from a previous study in our hospital, which were 30 and 10 seconds, respectively.<sup>[17]</sup> We assumed a between-group

difference in TTI of 5 seconds to be clinically significant. The sample size was calculated to be 64 per group at 80% power and a significance level of 0.05; we recruited 140 patients to compensate for possible dropouts. All statistical analyses were performed using SPSS, version 23.0 for Windows (IBM Corp, Armonk, NY). We used the Mann-Whitney *U* test for the TTI, IDS, and POGO scale. The independent *t* test was used for the other continuous data, and the chi-square or Fisher exact test was used for categorical data between groups. Data are shown as median (interquartile range [IQR]), mean  $\pm$  SD, or number of patients. Results were considered statistically significant when  $P < .05$ .

## 3. Results

A total of 140 patients completed this study (Fig. 1). The patient demographics and preoperative airway assessment findings were similar between the 2 groups (Table 1).

All patients were successfully intubated on the first attempt within 60 seconds. The results of the CL grade (1/2a/2b) (63/7/0 vs 43/24/3,  $P < .001$ ), POGO scale (median [IQR]) (100 [100–100] vs 100 [80–100],  $P < .001$ ), and IDS (median [IQR]) (0 [0–0] vs 0 [0–1],  $P < .001$ ) showed significantly better laryngeal visualization with the Pentax AWS compared with the McGrath VL. OELM was used for 5 patients in the McGrath VL group, whereas it was not performed at all in the Pentax AWS group; however, this difference was not statistically significant ( $P = .058$ ). Moreover, ease of intubation (1–5-point NRS: 17/44/7/2/0 vs 18/43/9/0/0,  $P = .661$ ) and the TTI (median [IQR]) (30 [27–34] vs 32 [27–35] seconds,  $P = .440$ ) were similar between the Pentax AWS and McGrath VL groups (Table 2 and Fig. 2).

Table 3 shows no significant differences in hemodynamic changes or BIS values during anesthesia induction between the 2 groups.

## 4. Discussion

This study showed the Pentax AWS was overwhelmingly superior with respect to glottic view and the POGO scale in patients with normal airways; however, using the Pentax AWS did not improve the ease of intubation, TTI, or first-attempt success rate compared with the McGrath VL. This is the first randomized clinical trial to compare routine intubation using the Pentax AWS and the McGrath VL. Further studies might be needed to compare these 2 VL devices in patients with difficult airways or cervical spine immobilization.

In general, most VLs can improve laryngeal visualization.<sup>[1,3,4]</sup> In a study using manikins with normal airway models, the Pentax AWS and McGrath VL showed a CL grade 1 view 96% and 91% of the time, respectively.<sup>[13]</sup> In another study using a manikin model with an immobilized cervical spine, the Pentax AWS and McGrath VL shows a CL grade 1 view 100% and 82.6% of the time, respectively.<sup>[18]</sup> In this study, using patients with normal airways, a CL grade 1 view was achieved significantly more often with the Pentax AWS compared with the McGrath VL (90.0% vs 61.4%). Levitan et al<sup>[19]</sup> measured a grid of dark squares and found that the Pentax AWS has a vertically longer view than the McGrath VL, which has slightly smaller view, and this can partly contribute to the superior laryngeal view of the Pentax AWS.

A better glottic view by VLs does not always guarantee an easy intubation.<sup>[3,11,12]</sup> The pharyngeal-laryngeal-tracheal axes are not aligned during intubation with the McGrath VL, and the stylet must often be bent more acutely than the conventional

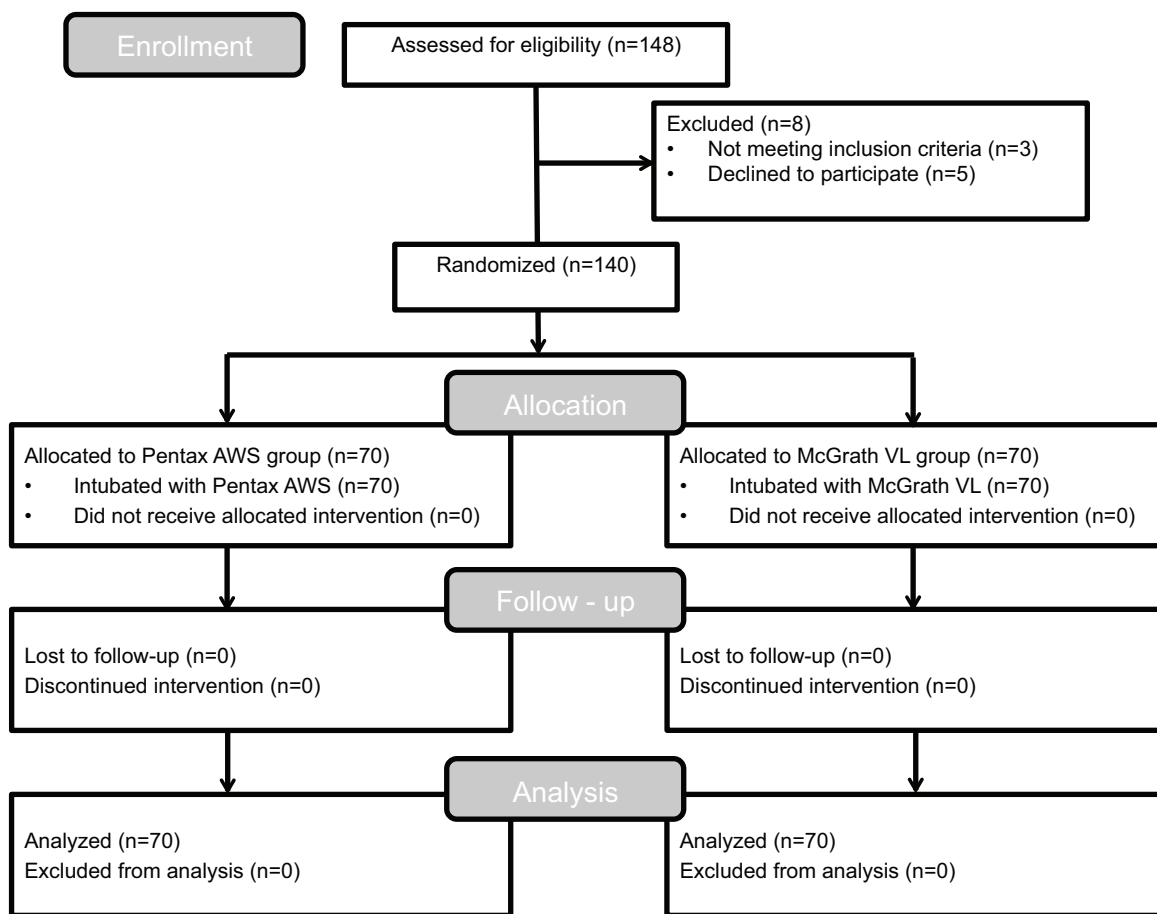


Figure 1. Patient allocation flow diagram.

35° “hockey stick” angle to enter the glottis that presents anteriorly,<sup>[2,20]</sup> which can prolong the TTI. In contrast, the Pentax AWS has an anatomically shaped blade and a channel for the ETT, which makes guiding the tube into the glottic opening quite easy.<sup>[8]</sup> The Pentax AWS was reported to have intubation times that were shorter than or similar to the McGrath VL in previous manikin studies.<sup>[13,18,21,22]</sup> Sharma et al<sup>[13]</sup> reported that anesthetists unfamiliar with videolaryngoscopy demonstrated higher intubation success rates and a greater ability to rapidly secure the airway with the Pentax AWS compared with the

McGrath VL in normal airway models. Other manikin studies also found that the TTI using the McGrath VL was significantly longer compared with other VLS, including the Pentax AWS; that study used a chest compression, immobilized cervical spine, and car victim model to simulate various difficult intubation situations.<sup>[18,21,22]</sup> In contrast, Komasa et al<sup>[23]</sup> found that the intubating time was longer with the Pentax AWS compared with the McGrath VL in patients who received cricoid pressure during intubation; the authors explained that this was due to the McGrath VL providing both an indirect and direct glottic view,

**Table 1**  
Patient characteristics.

	All (n = 140)	Pentax (n = 70)	McGrath (n = 70)	P value
Male	64 (45.7)	30 (42.9)	34 (48.6)	.497
Age, y	42 ± 12	41 ± 12	43 ± 12	.251
Weight, kg	67 ± 12	67 ± 12	66 ± 12	.918
Height, cm	165 ± 8	164 ± 8	165 ± 8	.532
ASA physical status (1/2)	111/29	55/15	56/14	.835
TMD, cm	9.3 ± 1.1	9.5 ± 1.1	9.2 ± 1.1	.103
Mouth opening, cm	4.6 ± 0.7	4.7 ± 0.8	4.5 ± 0.6	.155
ROM of cervical spine (normal/reduced/fixe)	140/0/0	70/0/0	70/0/0	1.000
Upper incisors (normal/absent/prominent)	135/5/0	67/3/0	68/2/0	1.000
Mallampati score (1/2/3)	60/68/12	32/31/7	28/37/5	.569

Values are presented as mean ± SD or number of patients (%).

ASA = American Society of Anesthesiologists, TMD = thyromental distance, ROM = range of motion.

**Table 2****Intubation profiles.**

	Pentax (n=70)	McGrath (n=70)	P value
Time to intubation, s	30 (20–48 [27–34])	32 (17–50 [27–35])	.440
IDS	0 (0–1 [0–0])	0 (0–2 [0–1])	<.001
POGO scale	100 (60–100 [100–100])	100 (40–100 [80–100])	<.001
Glottic grade (1/2a/2b/3/4)	63/7/0/0/0	43/24/3/0/0	<.001
OELM (–/+)	70/0	65/5	.058
First attempt failure (–/+)	70/0	70/0	1.000
Ease of intubation (1/2/3/4/5)	17/44/7/2/0	18/43/9/0/0	.661
Bleeding (none/trace/moderate/severe)	69/1/0/0	70/0/0/0	1.000
Sore throat (–/+)	60/10	53/17	.134
Hoarseness (–/+)	61/9	56/14	.254

Values are presented as median (range [IQR]) or number of patients.

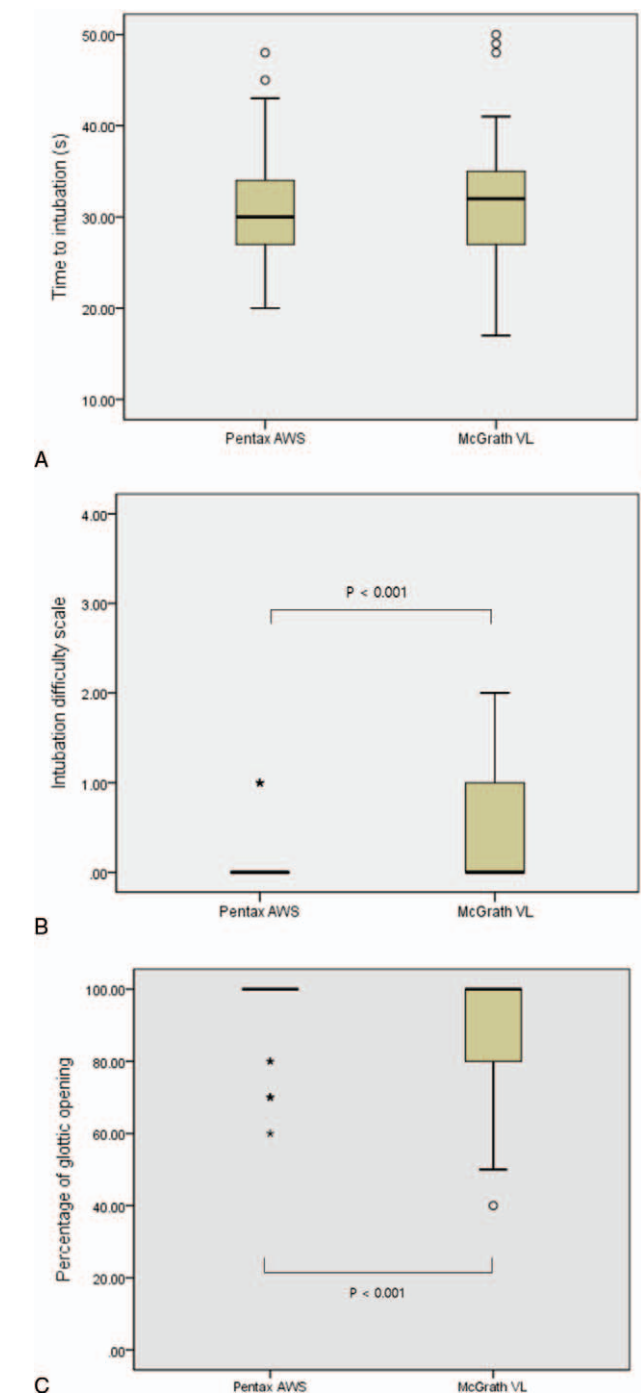
IDS=intubation difficulty scale, POGO=percentage of glottic opening, OELM=optimal external laryngeal manipulation.

whereas the Pentax AWS only provided an indirect view by video camera.

In this study, the Pentax AWS showed a similar TTI despite the superior laryngeal view compared with the McGrath VL. One possible explanation of our results is that the operators in this study have mostly used a Macintosh laryngoscope, which visualizes the glottis in a similar way to the McGrath VL; both apply pressure to the hyoepiglottic ligament at the vallecula, indirectly lifting the epiglottis. In contrast, the blade of the Pentax AWS is designed to directly lift the whole epiglottis to align the tube with the target sign on the LCD monitor.<sup>[19]</sup> A review article by Hoshijima et al<sup>[24]</sup> demonstrated that the Pentax AWS offered a superior glottic view than a Macintosh laryngoscope, but this was not associated with a shorter TTI. Another possible explanation for these results is that careful insertion and removal of the bulky blade of the Pentax AWS without touching the teeth took more time than insertion and removal of the McGrath VL. A previous review article discovered that there were more dental clicks and dental compression with the Pentax AWS.<sup>[24]</sup> If we had measured time separately, the time from sighting the glottis to passing the ETT through the vocal cords would have been much shorter in the Pentax AWS group compared with the McGrath VL group.

In this study, the median (IQR) TTI by 2 experienced anesthesiologists was 30 (27–34) seconds in the Pentax AWS group and 32 (27–35) seconds in the McGrath VL group; this is comparable with findings from previous studies. With the Pentax AWS, Hirabayashi et al<sup>[9]</sup> reported that the mean TTI by non-anesthesiology residents was 44 seconds; Teoh et al<sup>[25]</sup> reported a median TTI of 18.9 seconds by anesthesiologists who had used the Pentax AWS at least 30 times previously. With the McGrath VL, Walker et al<sup>[26]</sup> reported that the median TTI was 47 seconds by inexperienced anesthesiologists, and Shippey et al<sup>[5]</sup> reported that median TTI was 24.7 seconds by experienced anesthesiologists. The different definition of TTI in each study might have influenced the results.

The Pentax AWS has a channel with which to guide the ETT; therefore, the lack of a stylet and the ability to continuously observe the intubation procedure can reduce the risk of oral and pharyngeal injury, including mild mucosal bleeding and sore throat.<sup>[10,27]</sup> We therefore expected fewer patients would experience oropharyngeal bleeding, sore throat, and hoarseness in the Pentax AWS group. Our results showed fewer patients had



**Figure 2.** Box plots illustrating time to intubation (TTI) (A), intubating difficulty scale (B), and percentage of glottic opening (C) in the Pentax and McGrath groups. The horizontal line in the box, the outer horizontal lines of the box, and error bar indicate median, IQR, and 95% confidence interval (CI), respectively. Open circles and asterisks are outliers and extreme outliers.

sore throat (14.3% vs 24.3%) and hoarseness (12.9% vs 20.0%) in the Pentax AWS group compared with the McGrath VL group; however, there were no statistically significant difference between the groups with comparable cuff pressure. Furthermore, the incidence of oropharyngeal bleeding was very rare in both groups; there was only 1 case with trace bleeding in the Pentax AWS group and there were no cases with bleeding in the McGrath VL group.

**Table 3**  
**Hemodynamic changes during anesthesia induction.**

	Group	T0	T1	T2	T3
MAP, mm Hg	Pentax	100 ± 15	86 ± 16	77 ± 13	110 ± 20
	McGrath	99 ± 14	85 ± 16	75 ± 13	112 ± 20
HR, beats/min	Pentax	77 ± 13	72 ± 10	72 ± 10	89 ± 13
	McGrath	77 ± 15	73 ± 12	70 ± 11	87 ± 17
SpO <sub>2</sub> , %	Pentax	98.4 ± 1.4	99.7 ± 0.6	99.6 ± 0.6	99.3 ± 1.5
	McGrath	98.3 ± 1.2	99.7 ± 0.5	99.6 ± 0.6	99.5 ± 0.7
BIS	Pentax	98.6 ± 1.0	43.8 ± 13.7	42.2 ± 9.7	43.8 ± 11.1
	McGrath	98.8 ± 0.6	47.1 ± 14.9	41.8 ± 9.1	40.8 ± 9.8

Values are presented as mean ± SD.

MAP = mean arterial pressure, HR = heart rate, SpO<sub>2</sub> = oxygen saturation, BIS = bispectral index, T0 = baseline, T1 = 1 min after induction, T2 = prior to intubation, T3 = 1 min after intubation.

As matters stand today, the main challenges are to determine to what extent it should be used for routine clinical practice and to determine which devices are the best. Several editorialists insist VLs are the first line device for unanticipated difficult intubation.<sup>[3]</sup> However, the first line use of VLs for routine tracheal intubation is still controversial even though VLs reduce the risk of difficulties and eliminate the need for the intubating anesthesiologist to stop to exchange with another device.<sup>[1,11]</sup> In our study, the Pentax AWS and McGrath VL showed similar TTI and first-attempt success rates for routine clinical practice, so choosing between the 2 devices depends on the availability at the individual facilities and the anesthesiologist's familiarity.

This study has several limitations. First, it was not possible to blind the intubating anesthesiologist as to which airway instrument was being used. Second, the anesthesiologists in this study were much more familiar with the McGrath VL, which is similar to the blade of the Macintosh laryngoscope, so they took relatively longer to intubate with the Pentax AWS than what was initially expected. Given the Pentax AWS visualizes the glottis similarly to the Miller laryngoscope, if the operators in this study had mostly used a Miller laryngoscope for routine intubation, the intubating time using the Pentax AWS may have been different.

In conclusion, the Pentax AWS provided a significantly better glottic view compared with the McGrath VL; however, intubation times and ease of intubation were similar using both devices in patients with normal airways.

## References

- Zaouter C, Calderon J, Hemmerling TM. Videolaryngoscopy as a new standard of care. *Br J Anaesth* 2015;114:181–3.
- Taylor AM, Peck M, Launcelott S, et al. The McGrath® Series 5 videolaryngoscope vs the Macintosh laryngoscope: a randomised, controlled trial in patients with a simulated difficult airway. *Anaesthesia* 2013;68:142–7.
- Paolini JB, Donati F, Drolet P. Review article: video-laryngoscopy: another tool for difficult intubation or a new paradigm in airway management? *Can J Anaesth* 2013;60:184–91.
- Frerk C, Mitchell VS, McNarry AF, et al. Difficult Airway Society 2015 guidelines for management of unanticipated difficult intubation in adults. *Br J Anaesth* 2015;115:827–48.
- Shippey B, Ray D, McKeown D. Use of the McGrath videolaryngoscope in the management of difficult and failed tracheal intubation. *Br J Anaesth* 2008;100:116–9.
- Asai T, Murao K, Shingu K. Training method of applying pressure on the neck for laryngoscopy: use of a videolaryngoscope. *Anaesthesia* 2003;58:602–3.
- Asai T, Enomoto Y, Shimizu K, et al. The Pentax-AWS videolaryngoscope: the first experience in one hundred patients. *Anesth Analg* 2008;106:257–9.
- Savoldelli GL, Schiffer E. Videolaryngoscopy for tracheal intubation: the guide channel or steering techniques for endotracheal tube placement? *Can J Anaesth* 2008;55:59–60.
- Hirabayashi Y, Seo N. Tracheal intubation by non-anesthesia residents using the Pentax-AWS airway scope and Macintosh laryngoscope. *J Clin Anesth* 2009;21:268–71.
- Suzuki A, Toyama Y, Katsumi N, et al. The Pentax-AWS® rigid indirect video laryngoscope: clinical assessment of performance in 320 cases. *Anaesthesia* 2008;63:641–7.
- Lafferty BD, Ball DR, Williams D. Videolaryngoscopy as a new standard of care. *Br J Anaesth* 2015;115:136–7.
- Larsson A, Dhonneur G. Videolaryngoscopy: towards a new standard method for tracheal intubation in the ICU? *Intensive Care Med* 2013;39:2220–2.
- Sharma DJ, Weightman WM, Travis A. Comparison of the Pentax Airway Scope and McGrath Videolaryngoscope with the Macintosh laryngoscope in tracheal intubation by anaesthetists unfamiliar with videolaryngoscopes: a manikin study. *Anaesth Intensive Care* 2010;38:39–42.
- Cormack RS, Lehane J. Difficult tracheal intubation in obstetrics. *Anaesthesia* 1984;39:1105–11.
- Levitan RM, Ochroch EA, Kush S, et al. Assessment of airway visualization: validation of the percentage of glottic opening (POGO) scale. *Acad Emerg Med* 1998;5:919–23.
- Adnet F, Borron SW, Racine SX, et al. The intubation difficulty scale (IDS): proposal and evaluation of a new score characterizing the complexity of endotracheal intubation. *Anesthesiology* 1997;87:1290–7.
- Lee J, Kim JY, Kang SY, et al. Stylet angulation for routine endotracheal intubation with McGrath videolaryngoscope. *Medicine (Baltimore)* 2017;96:e6152.
- Wetsch WA, Spelten O, Hellmich M, et al. Comparison of different video laryngoscopes for emergency intubation in a standardized airway manikin with immobilized cervical spine by experienced anaesthetists. A randomized, controlled crossover trial. *Resuscitation* 2012;83:740–5.
- Levitan RM, Heitz JW, Sweeney M, et al. The complexities of tracheal intubation with direct laryngoscopy and alternative intubation devices. *Ann Emerg Med* 2011;57:240–7.
- Shippey B, Ray D, McKeown D. Case series: the McGrath videolaryngoscope—an initial clinical evaluation. *Can J Anaesth* 2007;54:307–13.
- Komasawa N, Fujiwara S, Mihara R, et al. Comparison of McGrath and Pentax-AWS Airwayscope for tracheal intubation by anaesthesiologists during chest compression in a manikin: A randomised crossover trial. *Eur J Anaesthesiol* 2015;32:442–3.
- Wetsch WA, Carlitscheck M, Spelten O, et al. Success rates and endotracheal tube insertion times of experienced emergency physicians using five video laryngoscopes: a randomised trial in a simulated trapped car accident victim. *Eur J Anaesthesiol* 2011;28:849–58.
- Komasawa N, Kido H, Mihara R, et al. Comparison of cricoid pressure effect between McGRATH® MAC and Pentax-AWS Airwayscope®: a prospective randomized trials. *Am J Emerg Med* 2017;35:576–8.
- Hoshijima H, Kuratani N, Hirabayashi Y, et al. Pentax Airway Scope® vs Macintosh laryngoscope for tracheal intubation in adult patients: a systematic review and meta-analysis. *Anaesthesia* 2014;69:911–8.
- Teoh WH, Shah MK, Sia AT. Randomised comparison of Pentax AirwayScope and Glidescope for tracheal intubation in patients with normal airway anatomy. *Anaesthesia* 2009;64:1125–9.
- Walker L, Brampton W, Halai M, et al. Randomized controlled trial of intubation with the McGrath Series 5 videolaryngoscope by inexperienced anaesthetists. *Br J Anaesth* 2009;103:440–5.
- van Zundert A, Pieters B, van Zundert T, et al. Avoiding palatopharyngeal trauma during videolaryngoscopy: do not forget the 'blind spots'. *Acta Anaesthesiol Scand* 2012;56:532–4.