

Neuroprotective effect of ethanol in acute carbon monoxide intoxication

A retrospective study

Hyuk-Hoon Kim, MD, Sang Chun Choi, MD, Minjung Kathy Chae, MD, Young-Gi Min, MD*

Abstract

In acute carbon monoxide (CO) intoxication, treatment of neurologic injury and prevention of neurological sequelae are primary concerns. Ethanol is the one of the frequent substances which is co-ingested in intentional CO poisoning. Neuroprotective effect of ethanol was highlighted and demonstrated in isolated brain injury recently. We assessed the neuroprotective effect of ethanol in acute CO intoxication using magnetic resonance imaging (MRI).

We retrospectively reviewed medical records for patients who visited an emergency medical center of a university-affiliated hospital during a period of 73 months, from March 2009 to April 2015. Enrolled patients were divided into 2 groups, patients with or without abnormal brain lesion in brain MRI. Multivariate logistic regression analysis was performed to assess the factors associated with brain injury in MRI.

A total of 109 patients with acute CO intoxication were evaluated of which 66 (60.55%) tested positive in brain MRI. MRI lesion-positive patients were more likely to have electrocardiogram change, elevation of serum troponin I and s100 protein level and lower serum ethanol level. Serum ethanol positivity was an independent factor for prevalence of brain injury in MRI in acute CO poisoning.

This study revealed that ethanol which is co-ingested in acute CO intoxication may work the neuroprotective effect and could consequence more favorable neurological outcome in acute CO intoxication.

Abbreviations: CI = confidence interval, CO = carbon monoxide, DBP = diastolic blood pressure, DNS = delayed neurological sequelae, DWI = diffusion weighted imaging, ECG = electrocardiogram, ED = emergency department, EKG = electrocardiography, ETOH = ethanol, FLAIR = fluid-attenuated inversion recovery, GP = globus pallidus, HR = heart rate, MBP = mean blood pressure, MRI = magnetic resonance imaging, NMDA = *N*-methyl-D-aspartate, OBG = other basal ganglia, OR = odds ratio, SBP = systolic blood pressure, WM = white matter.

Keywords: brain injury, carbon monoxide, ethanol, magnetic resonance imaging, retrospective studies

1. Introduction

Carbon monoxide (CO) intoxication is one of the frequent causes of morbidity and mortality due to poisoning, and is one of the main causes of poisoning-related deaths in the United States.^[1,2] Signs and symptoms of intoxication vary from mild headache,

myalgia or dizziness to confusion, loss of consciousness, or death.^[3–5]

Even though mortality among patients admitted to the hospital has gradually decreased with time, until recently there has not been optimal methods to prevent and treat neurological injury. So, prevention and treatment of neurological injury and their sequelae have become the primary concerns in CO intoxication.^[6] Several methods have been suggested to evaluate brain injuries caused by CO intoxication as a means of evaluating neurological injury and predicting sequelae. One objective assessment of brain injury is through magnetic resonance imaging (MRI), a readily available and minimally invasive procedure.^[7–9]

Coingestion of a second substance in patients with intentional CO poisoning occurs frequently, in almost 50% of patients, and involves ethanol (ETOH) in over two-thirds of patients.^[10] In experimental and clinical studies, the neuroprotective effects of ETOH after isolated traumatic brain injury were postulated. Recent data have indicated the neuroprotective effects of ETOH in patients with moderate and traumatic brain injury. The mechanisms of this neuroprotective effect are inhibition of *N*-methyl-D-aspartate (NMDA) receptor channels, mitigation of systemic catecholamine surge, reduction of aquaporin-4, inhibition of glycolysis, and lowering of body temperature.^[11–14]

The aim of our study is to assess the neuroprotective effects of ETOH on neurological injury in acute CO intoxication by examination of brain lesions revealed by MRI.

Editor: Satyabrata Pany.

Authorship: HH and YG designed the study, analyzed, and interpreted the data. SC and MC supervised the conduct of study. HH drafted the manuscript and SC and MC contributed substantially to its revision. YG takes responsibility for the paper as a whole. All authors read and approved the final manuscript.

Ethical approval: This study was approved by the Institutional Review Board of Ajou University Medical Center (AJIRB-MED-MDB-16-477).

The authors have no conflicts of interest to disclose.

Department of Emergency Medicine, Ajou University School of Medicine, Suwon, Republic of Korea.

* Correspondence: Young-Gi Min, Department of Emergency Medicine, Ajou University School of Medicine, Suwon, Republic of Korea (e-mail: youngmd@me.com).

Copyright © 2018 the Author(s). Published by Wolters Kluwer Health, Inc. This is an open access article distributed under the Creative Commons Attribution-NoDerivatives License 4.0, which allows for redistribution, commercial and non-commercial, as long as it is passed along unchanged and in whole, with credit to the author.

Medicine (2018) 97:1(e9569)

Received: 14 August 2017 / Received in final form: 14 November 2017 /

Accepted: 14 December 2017

<http://dx.doi.org/10.1097/MD.0000000000009569>

2. Methods

This study was conducted retrospectively by reviewing medical records for patients who visited an emergency medical center of a university-affiliated hospital during a period of 73 months (March 2009–April 2015). This study was approved by the Institutional Review Board of Ajou University Medical Center (AJIRB-MED-MDB-16-477). Requirement of patient consent was waived due to the study's retrospective nature.

2.1. Enrolled patients and study setting

The enrolment criteria were diagnosis of acute CO poisoning and the measurement of the serum ETOH level and history of brain MRI during admission. The diagnosis of acute CO poisoning was established according to the history, clinical characteristics, physical examination, and blood carboxyhemoglobin levels $> 3\%$ in nonsmokers or $> 10\%$ in smokers. The exclusion criteria were history of stroke, congenital brain anomaly, history of brain trauma, and surgery for avoiding false positives in the group selection process. Cases with missing or insufficient data were also excluded. The enrolled patients were divided into 2 groups: patients with or without abnormal brain lesion in T2-weighted imaging, fluid-attenuated inversion recovery (FLAIR) imaging, and diffusion weighted imaging (DWI). Any area of increased signal intensity in the T2 and FLAIR sequences was considered abnormal. Moreover, in DWI sequences, any area of high signal intensity in b value = 500 and b value = 1000 showing signal loss in apparent diffusion coefficient maps were considered abnormal.^[15] To decide whether abnormal lesion is existed or not, the official readout data written by professional radiologist were reviewed (Fig. 1).

2.2. Data collection

Standardized extraction of demographic, clinical, laboratory, and radiological data using medical records was performed by 2 trained emergency physicians. Any discrepancy between the datasets extracted by 2 emergency physicians was resolved by a third physician. The physicians were blinded to the patient's serum laboratory study results. The sex and age of patients, symptoms and physical findings at presentation, electrocardiogram (ECG), and time interval from presentation at the emergency department (ED) to MRI were recorded. Laboratory studies including the evaluation of the serum levels of CO cardiac enzyme, S100 protein, ETOH, lactate, and pH were performed when the patient visited the ED. Serum ETOH level was measured using a quantitative chemistry analyzer (Roche Cobas Integra 800; Roche Diagnostics GmbH, Mannheim, Germany). Conventional brain MRI and DWI was performed using a Philips 3.0 Teslon device (Philips North America Corporation, Andover, MA). T1 weighted (TR 400–500, TE 10, Slice thickness: 5 mm), T2 weighted (TR: 3100–3200, TE: 80), and FLAIR images (TR: 8000–10000, TE: 125) in sagittal, axial, and coronal sections and DWI in axial sections were performed for each patient.

2.3. Statistical analysis

The study population was divided into 2 groups: patients who tested positive for brain MRI (MRI lesion positive) and patients who tested negative for brain MRI (MRI lesion negative). All data are expressed as the mean \pm standard deviations or the median (interquartile range) or using standard error, as appropriate. The significance of intergroup differences was assessed by Fisher exact

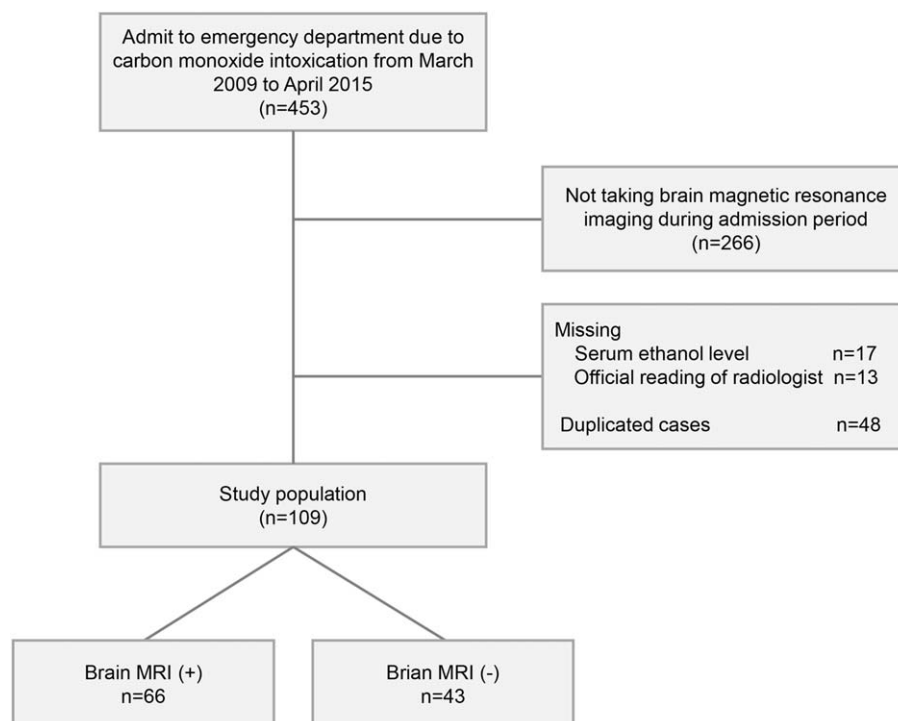


Figure 1. Flow chart reveals the reason for, and number of, patient inclusions, and exclusions.

Table 1**Comparison of characteristics of enrolled patients.**

	MRI lesion (+) (n = 66)	MRI lesion (-) (n = 43)	P-value
Demographics			
Age, years	40.20 ± 15.09	37.70 ± 13.95	>.05
<25, %	15.15	16.28	
25–49, %	62.12	69.77	
50–74, %	18.18	11.63	
≥75, %	4.55	2.33	
Male, %	69.70	58.14	>.05
Vital parameters on arrival to ER			
Heart rate, beats/min	101.05 ± 21.20	96.511 ± 23.81	>.05
SBP, mm Hg	120.5 ± 25.20	123.53 ± 16.10	>.05
DBP, mm Hg	72.59 ± 17.39	74.77 ± 12.23	>.05
Signs and Symptoms on arrival to ER			
Mental status, %			<.05
Alert	15.15	41.86	
Verbal	13.64	16.28	
Pain	63.64	39.53	
Unresponsive	7.58	2.33	
Altered mental status, %	84.85	58.14	<.05
Headache, %	4.55	4.65	>.05
Chest pain, %	3.03	4.65	>.05
Nausea/Vomit, %	1.52	2.32	>.05
Dyspnea, %	4.65	4.55	>.05
Seizure, %	0	0	>.05
Time to MRI, min	8118.74 [145–36160]	10142.49 [116–63310]	>.05
ECG positivity, %	39.39	18.60	<.05

DBP = diastolic blood pressure, ECG = electrocardiogram, ER = emergency room, MRI = magnetic resonance imaging, SBP = systolic blood pressure.

test for categorical variables and Mann–Whitney U test for continuous variables. A univariate analysis was performed to identify factors associated with brain injury in MRI. Logistic regression analysis was performed to identify ETOH that could be considered negatively correlated with abnormal brain lesion in CO intoxicated patient. Two-sided *P* values <.05 were considered statistically significant. The statistical analysis was performed using R program software for Mac, version 3.2.2 (The R Foundation for Statistical Computing, c/o Institute for Statistics and Mathematics, Wirtschaftsuniversität Wien, Vienna, Austria).

3. Results

3.1. Comparisons of characteristics in the 2 groups

A total of 109 patients with acute CO intoxication were enrolled. Sixty-six (60.55%) were positive in brain MRI. Median age of patients was 39.21 ± 14.64 years and 65.14% (n = 71) were male.

Mean blood pressure was 89.53 ± 16.43 mm Hg and mean heart rate was 99.26 ± 22.27 beats per min. There were no significant differences in age, sex, and vital parameters between the 2 groups. MRI lesion positive patients were more likely to develop mental status changes (*P* <.05) compared with MRI lesion negative patients. There were no significant differences in clinical sign and symptoms on presentation and time interval from presentation on ED to MRI (Table 1).

3.2. Comparisons of laboratory results between MRI lesion-positive and MRI lesion-negative patients

There were significant differences in serum lactate, serum S100 protein, serum cardiac enzyme levels, and serum ETOH levels between the 2 groups. Serum carboxyhemoglobin level and serum pH level did not differ significantly between the 2 groups (Table 2).

Table 2**Comparison of laboratory results.**

	MRI lesion (+)		MRI lesion (-)		P-value
	Mean	SE	Mean	SE	
CO, %	18.29	2.01	15.68	1.97	>.05
Lactate, mmol/L	4.99	0.49	3.48	0.37	<.05
pH	7.36	0.01	7.41	0.01	>.05
ETOH, mg/dL	20.75	7.24	40.79	10.77	<.05
S100 protein, μg/L	0.47	0.11	0.18	0.05	<.05
Troponin I, ng/dL	1.12	0.35	0.26	0.10	<.05

CO = carbon monoxide, ETOH = ethanol, MRI = magnetic resonance imaging, SE = standard error.

Table 3
Univariate and multivariate regression analysis.

Variables	Univariate analysis		Multivariate analysis	
	OR (95% CI)	P-value	OR (95% CI)	P-value
Age, year				
25–49	0.95 (0.31–2.78)	>.05	–	–
50–74	1.68 (0.41–7.31)	>.05	–	–
≥75	2.10 (0.21–47.49)	>.05	–	–
Male	1.65 (0.74–3.71)	>.05	–	–
HR	1.01 (0.99–1.03)	>.05	–	–
SBP	0.99 (0.98–1.01)	>.05	–	–
DBP	0.99 (0.97–1.02)	>.05	–	–
MBP	0.99 (0.97–1.01)	>.05	–	–
Altered consciousness	3.00 (1.21–7.73)	<.05	2.31 (0.76–7.21)	>.05
Lactate	1.15 (1.02–1.34)	<.05	1.17 (1.00–1.39)	>.05
ECG change	2.84 (1.17–7.46)	<.05	1.73 (0.61–5.30)	>.05
S100	7.52 (1.59–66.33)	<.05	2.50 (0.94–18.42)	>.05
ETOH positivity	0.24 (0.10–0.60)	<.05	0.26 (0.08–0.79)	<.05
Troponin	1.86 (1.15–3.85)	<.05	1.31 (0.94–2.66)	>.05

CI=confidence interval, DBP=diastolic blood pressure, ECG=electrocardiogram, ETOH = ethanol, HR=heart rate, MBP=mean blood pressure, OR=odds ratio, SBP=systolic blood pressure.

3.3. Analysis for factors associated with positive MRI lesions

On univariate analysis, the significant factors associated with MRI lesion positivity were as follows: mental status ($P<.05$), serum lactate level ($P<.05$), ECG change ($P<.05$), serum ETOH positivity ($P<.05$), serum S100 level ($P<.05$), and serum troponin I level ($P<.05$). After adjusting for all confounding factors in a multivariate regression analysis, positive ETOH was an independent predictor for MRI lesion in patients with acute CO intoxication (Table 3).

3.4. Distribution of brain lesion according to ETOH positivity

The most frequently injured area in brain of patients with acute CO intoxication was the white matter (WM) in ETOH-positive patients and the globus pallidus (GP) in ETOH-negative patients (Fig. 2).

4. Discussion

No clinical study about the neuroprotective effect of ETOH in acute CO intoxication has been reported to our knowledge.

Presently, acutely CO-intoxicated patients who had co-ingested ETOH had lower brain injury events in brain MRI. ETOH may have protective effect on brain injury in acute CO intoxication (odds ratio: 0.24, $P<.05$).

ETOH intoxication was thought to be associated with worse outcomes generally. ETOH can be detrimental to the brain in several ways, including NMDA receptor supersensitivity followed by excitotoxicity, alcohol-induced oxidative stress of neurons, and promising growth factor secretion.^[16–18] However, several beneficial effects of ETOH have been previously postulated by various mechanisms, which include inhibition of NMDA, moderation of systemic catecholamine surge, implied participation of aquaporin-4 in the development of cerebral edema suppression, reduction of hyperglycolysis, and lowering body temperature.^[11–14] Brain injuries caused by CO intoxication are explained by several pathophysiological mechanisms, which include dopamine excess followed by hypoxic stress, oxidative stress, lipid peroxidation, and catecholamine crisis.^[6] One of the ETOH-related mechanisms could be a catecholamine crisis activated by sympathetic activities and the subsequent increase in catecholamine levels in synapses or nerve terminals, particularly in the limbic system in the brain. A neuroprotective effect of ETOH on brain injury in CO intoxication could derive

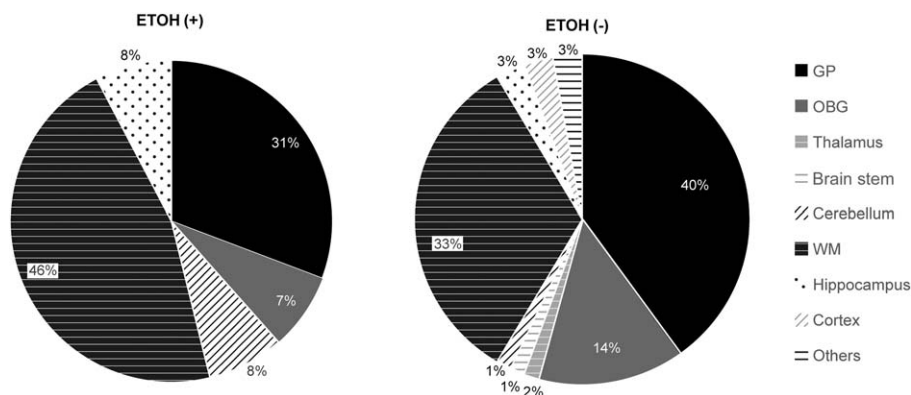


Figure 2. Distribution of brain lesion according to serum ethanol positivity. ETOH=ethanol, GP=globus pallidus, OBG=other basal ganglia, WM=white matter.

from the sedative effects of ETOH, which could mitigate the sympathetic activities and systemic catecholamine crisis. Dopamine excess followed by hypoxic stress, which could cause serotonergic axonal injury and secondary myelin damage in brain, may be reduced by ETOH. Some experimental studies have shown the inhibitory effect of ETOH on evoked dopamine neurotransmission in the brain.^[19,20]

The neuroprotective effect of ETOH may also have been evident in the distribution of abnormal brain lesions according to serum ETOH positivity in our study (Fig. 2). In acute CO intoxication, the GP is considered most vulnerable to catecholamine crisis, and the GP and other basal ganglia are commonly affected by brain lesions according to MRI analysis in the acute phase of CO intoxication.^[9] Involvement of the GP is more frequent in ETOH-negative patients than in ETOH-positive patients. These differences in the distribution of brain lesions between ETOH positive group and ETOH negative patients may reflect the ETOH-related mitigation of the catecholamine crisis.

The other difference in the distribution of brain lesion which is the predominance of WM lesion in ETOH-positive patients may be also explained by the effect of ETOH. Even though the WM is frequently injured in acute CO intoxication, patients with ETOH consumption, whether acute or chronic, have also shown signal abnormalities in their WMs of brain in MRI studies.^[24] And the protective effect of ETOH in GP which considered as mainstay could have elevated the portion of involvement of WM lesion as a result of the decrease portion of GP in ETOH-positive patients.

There were 6 laboratory parameters which are used for comparing 2 groups: MRI lesion-positive group and MRI lesion-negative group. Serum CO level which is generally considered as not related to neurologic injury after CO poisoning also did not show significant difference between groups. And no differences in serum pH level between groups imply that there was no significant distinction in acid–base status between the groups. Among the laboratory results in our study, the levels of serum S100 protein, serum troponin I, and lactate were elevated. These are considered as possible prognostic markers for delayed neurological sequelae (DNS).^[21–23] DNS is characterized by variable degrees of cognitive deficits, personality changes, movement disorders, and focal neurologic deficits, which can arise 3 to 240 days after apparent recovery in acute CO intoxication. These predictive markers for DNS were significantly elevated in the MRI lesion positive group in our study. Elevations of these prognostic markers could imply more prevalence of DNS among MRI lesion positive patients.

We suggest that reduction of the prevalence of brain injury by a neuroprotective effect of ETOH in CO intoxication could be related to the finding of less abnormal brain MRI and may also be related to a lower prevalence of DNS.

This study has several limitations. It was a retrospective medical record review study rather than a randomized study. The relatively small sample size, caused by low frequency of disease and high price of MR devices, and lack of data about the duration of CO intoxication, co-intoxication of possible other drugs or gas, the neurological status of patients due to incompleteness of medical records, are also considered as study limitations. We could not confirm whether the brain injury existed or not based on abnormal brain MRI findings at a single phase after CO intoxication in our study. We also believe that the study model designed with subgroup analysis according to the chronicity of ETOH consumption would help to improve the reliability of our results and better understand the mechanism of ETOH protective effects on CO poisoning. More detailed study including serial evaluation

of brain MRIs with proper time intervals and calculation of brain volume as a surrogate of chronic alcoholic MRI changes for further investigation will be needed in the future.

5. Conclusion

This study investigated the protective effect of ETOH in acute CO intoxication. Serum ETOH positivity was an independent predictor for brain injury in MRI. It reverses the myth that ETOH is harmful to the brain in cases of acute CO intoxication. We believe that ETOH co-ingestion in CO poisoning could have positive effects on DNS which is the primary concern in acute CO intoxication, recently. Further prospective studies are needed to assess whether ETOH truly prevents brain injury and DNS in acute CO intoxication.

Acknowledgments

The authors would like to thank all members and personnel of Department of Emergency Medicine of Ajou University School of Medicine.

References

- Ernst A, Zibrak JD. Carbon monoxide poisoning. *N Engl J Med* 1998;339:1603–8.
- Weaver LK. Carbon monoxide poisoning. *Crit Care Clin* 1999;15:297–317.
- Thom SR, Taber RL, Mendiguren II, et al. Delayed neuropsychologic sequelae after carbon monoxide poisoning: prevention by treatment with hyperbaric oxygen. *Ann Emerg Med* 1995;25:474–80.
- Kwon OY, Chung SP, Ha YR, et al. Delayed postanoxic encephalopathy after carbon monoxide poisoning. *Emerg Med J* 2004;21:250–1.
- Hampson NB, Little CE. Hyperbaric treatment of patients with carbon monoxide poisoning in the United States. *Undersea Hyperb Med* 2005;32:21–6.
- Oh S, Choi SC. Acute carbon monoxide poisoning and delayed neurological sequelae: a potential neuroprotection bundle therapy. *Neural Regen Res* 2015;10:36–8.
- Lo CP, Chen SY, Lee KW, et al. Brain injury after acute carbon monoxide poisoning: early and late complications. *AJR Am J Roentgenol* 2007;189:W205–11.
- O'Donnell P, Buxton PJ, Pitkin A, et al. The magnetic resonance imaging appearances of the brain in acute carbon monoxide poisoning. *Clin Radiol* 2000;55:273–80.
- Beppu T. The role of MR imaging in assessment of brain damage from carbon monoxide poisoning: a review of the literature. *AJNR Am J Neuroradiol* 2014;35:625–31.
- Hampson NB, Bodwin D. Toxic CO-ingestions in intentional carbon monoxide poisoning. *J Emerg Med* 2013;44:625–30.
- Collins MA, Neafsey EJ. Alcohol, excitotoxicity and adult brain damage: an experimentally unproven chain-of-events. *Front Mol Neurosci* 2016;9:8.
- Tureci E, Dashti R, Tanriverdi T, et al. Acute ethanol intoxication in a model of traumatic brain injury: the protective role of moderate doses demonstrated by immunoreactivity of synaptophysin in hippocampal neurons. *Neurol Res* 2004;26:108–12.
- Goodman MD, Makley AT, Champion EM, et al. Preinjury alcohol exposure attenuates the neuroinflammatory response to traumatic brain injury. *J Surg Res* 2013;184:1053–8.
- Salim A, Teixeira P, Ley EJ, et al. Serum ethanol levels: predictor of survival after severe traumatic brain injury. *J Trauma* 2009;67:697–703.
- Sener RN. Acute carbon monoxide poisoning: diffusion MR imaging findings. *AJNR Am J Neuroradiol* 2003;24:1475–7.
- Crews FT, Steck JC, Chandler LJ, et al. Ethanol, stroke, brain damage, and excitotoxicity. *Pharmacol Biochem Behav* 1998;59:981–91.
- Montoliu C, Valles S, Renau-Piqueras J, et al. Ethanol-induced oxygen radical formation and lipid peroxidation in rat brain: effect of chronic alcohol consumption. *J Neurochem* 1994;63:1855–62.
- MacLennan AJ, Lee N, Walker DW. Chronic ethanol administration decreases brain-derived neurotrophic factor gene expression in the rat hippocampus. *Neurosci Lett* 1995;197:105–8.

- [19] Budygin EA, Phillips PE, Robinson DL, et al. Effect of acute ethanol on striatal dopamine neurotransmission in ambulatory rats. *J Pharmacol Exp Ther* 2001;297:27–34.
- [20] Schilaty ND, Hedges DM, Jang EY, et al. Acute ethanol inhibits dopamine release in the nucleus accumbens via alpha6 nicotinic acetylcholine receptors. *J Pharmacol Exp Ther* 2014;349:559–67.
- [21] Park E, Ahn J, Min YG, et al. The usefulness of the serum s100b protein for predicting delayed neurological sequelae in acute carbon monoxide poisoning. *Clin Toxicol (Phila)* 2012;50:183–8.
- [22] Hu M-H, Huang J-L, Lin K-L, et al. Risk factors for delayed neuropsychiatric sequelae in carbon monoxide poisoning: ten years' experience in a pediatric emergency department. *J Clin Toxicol* 2012;2:124.
- [23] Kao LW, Nanagas KA. Carbon monoxide poisoning. *Emerg Med Clin North Am* 2004;22:985–1018.
- [24] Bjork JM, Gilman JM. The effects of acute alcohol administration on human brain: Insights from neuroimaging. *Neuropharmacology* 2014;84:101–10.