

Visual Diagnosis in Emergency Medicine

Lymphatic-Venous Malformation Presenting as a Mediastinal Mass in a 6-Year-Old Boy

Noh Moon Lim, MD BA,* Jeon Yeob Jang, MD PHD,† Ji Eun Park, MD PHD,‡ Seokhwi Kim, MD PHD,§ and Jung Heon Kim, MD MA||

*Departments of Pediatrics, Ajou University School of Medicine, 164 World cup-ro, Yeongtong-gu, Suwon, Republic of Korea,

†Departments of Otolaryngology, Ajou University School of Medicine, 164 World cup-ro, Yeongtong-gu, Suwon, Republic of Korea,

‡Departments of Radiology, Ajou University School of Medicine, 164 World cup-ro, Yeongtong-gu, Suwon, Republic of Korea,

§Departments of Pathology, Ajou University School of Medicine, 164 World cup-ro, Yeongtong-gu, Suwon, Republic of Korea, and

||Departments of Emergency Medicine, Ajou University School of Medicine, 164 World cup-ro, Yeongtong-gu, Suwon, Republic of Korea

Reprint Address: Jung Heon Kim, Department of Emergency Medicine, Ajou University School of Medicine, 164 World cup-ro, Yeongtong-gu, Suwon 16499, Republic of Korea

□ **Keywords—Child; Lymphatic Abnormalities; Lymphocele; Mediastinal Diseases; Neck Pain; Vascular Malformations**

Introduction

Among the slow-flow vascular malformations in children, lymphatic malformation (LM; formerly known as lymphangioma) typically develops in the neck (75–90%), with the posterior triangle being the most commonly affected site (1,2). Ninety percent of the entity is detected in children younger than 2 years (2). LM tends to behave like lymphatic-venous malformation (LVM; formerly, lymphangiohemangioma), but these two entities are clinically indistinguishable (3,4). This article describes a rare case of LVM, presenting as a new-onset, cervical mass extending to the mediastinum in a school-aged boy, that is, an unusual location and age for the malformation.

CASE REPORT

A previously healthy 6-year-old boy with a 1-day history of an enlarging right cervical mass visited the emergency

department in December 2021. One day prior to the visit, the child played tag with a friend who pulled a hood covering the boy's head. On the day of the visit, a 2-cm mass had appeared on his neck, which enlarged to 5 cm over the subsequent 3 h, as reported by his mother. The boy was alert, well looking, afebrile, and without dyspnea, dysphagia, or nuchal deformity. The 5-cm, minimally tender, mobile, fluctuant, flesh-colored right cervical mass was located on the lower region of the posterior triangle (Figure 1A). There was no noted erythema, necrosis, or warmth. At this point, we presumed the cervical mass to be LM, based on its location, mobility, and consistency.

The initial chest radiograph showed a right superior mediastinal mass (Figure 1B). Computed tomography depicted a large, well-defined, multi-loculated mass in the right lower neck and anterosuperior mediastinum. The mass compressed the junction between the right internal jugular vein and superior vena cava (SVC) (Figure 2A). The lesion was further detailed by a sonographic finding suggestive of internal hemorrhage (Figure 2B). On the ultrasound (US), the internal jugular vein appeared patent despite the venous compression on computed tomography (Figure 2B). Based on these findings, the radiographic diagnosis was LVM with internal hemorrhage. The boy

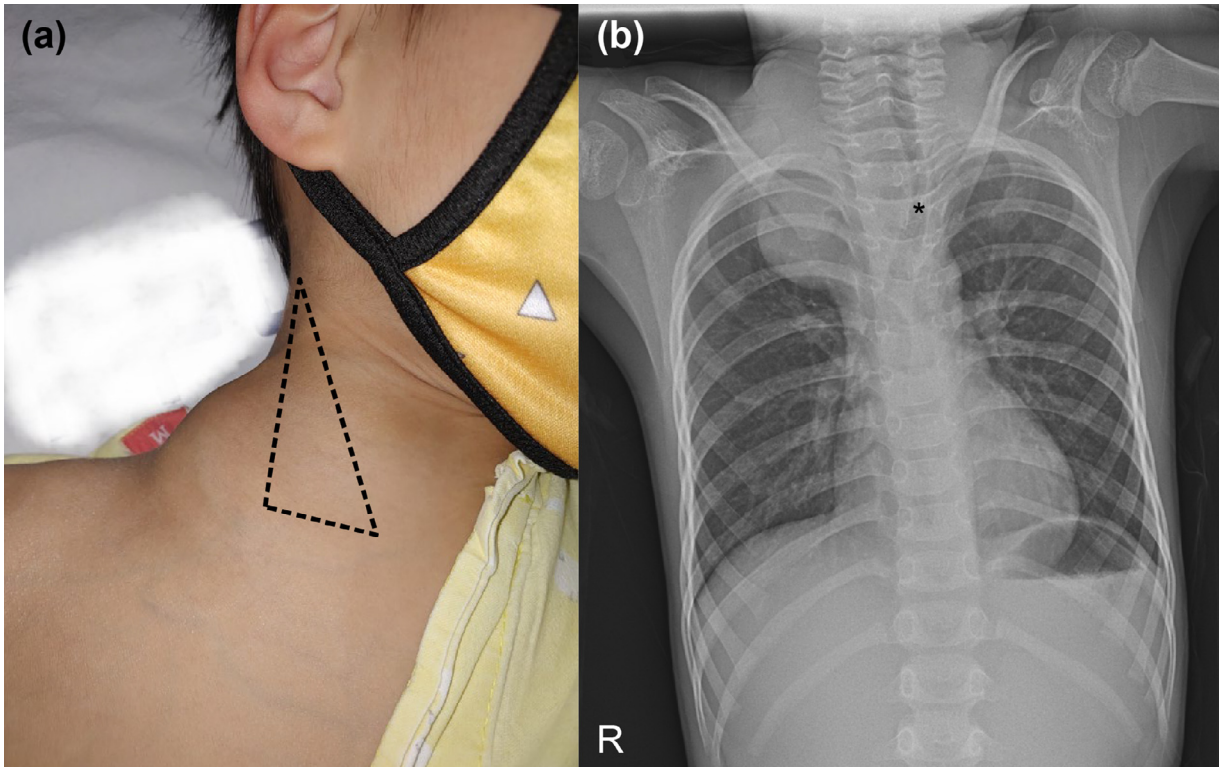


Figure 1. Location of the mass. (A) The 5-cm-sized mass is seen on the lower posterior triangle of the boy's right neck (dashed line). This location is consistent with the neck levels III–Vb. (B) The initial chest radiograph shows a right superior mediastinal mass with the trachea deviated to the left side (asterisk). Published under written consent of the boy's legal guardian.

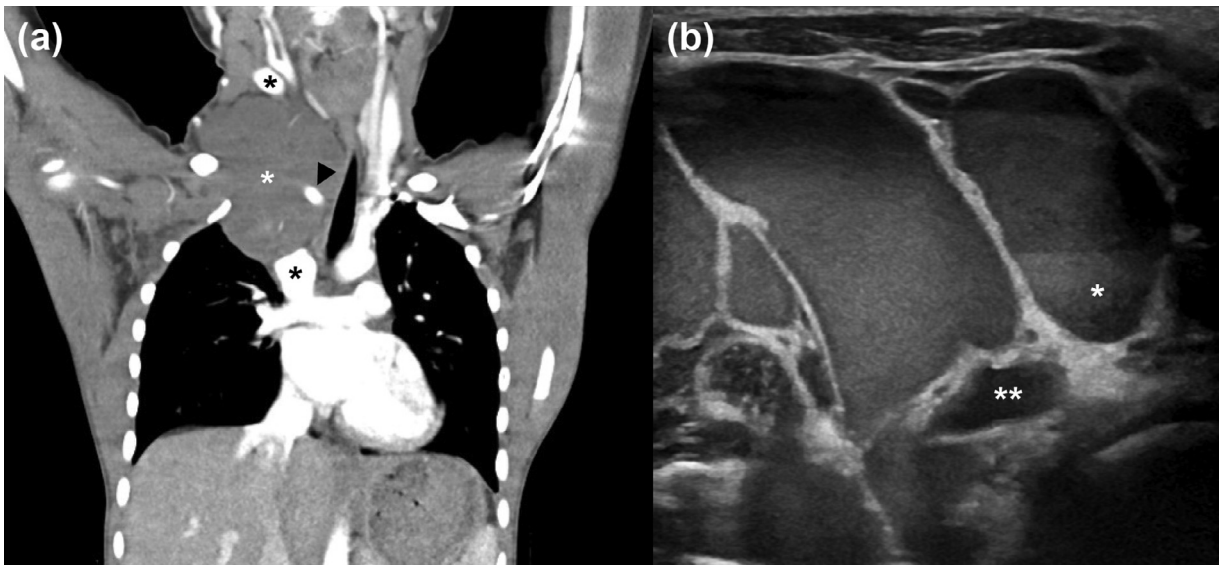


Figure 2. Findings of the (A) initial computed tomography (CT) and (B) ultrasound, suggesting lymphatic-venous malformation with internal hemorrhage. (A) On the CT, a 6.5 × 3.5 × 7.3-cm sized, well-defined, multi-loculated cystic, low-density mass (white asterisk) spans from the neck to the mediastinum. The mass interrupts the junction between the right internal jugular vein and superior vena cava (black asterisks), encases the brachiocephalic trunk (arrowhead), and compresses the trachea. (B) The sonogram shows the multi-loculated cyst with fluid-fluid level, which was considered an internal hemorrhage (asterisk). The internal jugular vein remains patent (double asterisks) despite the interruption between the two large veins on CT.

exhibited no signs of SVC syndrome, airway obstruction, or infection. Because congenital malformation was considered, the mother was questioned regarding further medical history. According to her, he had experienced the intermittent appearance and disappearance of the mass at the same location. The episodes were related to pharyngitis, and at the time, the mass had been quite small. The laboratory findings were unremarkable. The boy was hospitalized in the ward.

On day 3, the mass was dissected and excised by a head and neck surgeon and a thoracic surgeon. Intraoperatively, the mass spanned from the right neck levels III–V to the paratracheal and upper thoracic areas, with intralesional hemorrhage and necrosis (see gross findings in Supplementary Figure 1, available online). The diagnosis of LVM was pathologically confirmed with a lymphatic-venous connection in a single channel (Supplementary Figure 2, available online). The boy was discharged uneventfully on the following day. His legal guardian provided written consent for the publication of this report.

Discussion

Initially, the cystic mass in the neck and mediastinum was presumed to be LM. This presumptive diagnosis was modified to LVM by the clinical and imaging findings suggestive of the vascular components within the lesion: the sudden swelling after a minor injury, internal hemorrhage on US, and lack of SVC syndrome despite the venous compression. The LVM was confirmed using immunohistochemical markers, which distinguish between vascular and lymphatic components in the same lesion (Supplementary Figure 2) (5,6).

This case is consistent with previous reports in terms of the location, lack of SVC syndrome, and pathological findings (Supplementary Table 1, available online) (3–9). Among the 8 reported patients, 5 were school-aged or adolescent, and 3 had known vascular malformations. In our case, SVC syndrome did not develop despite the rapid progression, size, and location of lesion, as well as the compression of the large veins (Figure 2A). This was likely due to the liquidity of the lesion and US-confirmed venous patency.

This case provides an opportunity for mind-mapping differential diagnosis of cervical or mediastinal cystic masses. The cyst, located superficially, was suggestive of congenital neck cysts, such as thyroglossal duct cyst (2). Such cysts other than LM were excluded based on the location at the posterior triangle where LM typically

arises. Inflammatory neck masses, such as lymphadenitis, were ruled out due to the location, consistency, and sonographic findings. The involvement of the neck through the anterosuperior mediastinum excluded the possibility of other mediastinal cysts. Bronchogenic cyst is usually found at the level of the carina in the middle mediastinum, not extending into the neck (10). Unlike LVM, congenital pulmonary airway malformation and congenital lobar emphysema are located in the lung parenchyma (10). Although the mediastinal location itself suggested lymphoma, the cyst did not show relevant clinical signs or imaging findings.

In summary, a cystic mass in the neck or mediastinum indicates LM. In this circumstance, LVM was considered based on the sudden swelling after a minor injury, internal hemorrhage, and absence of SVC syndrome despite the mediastinal involvement.

Supplementary Materials

Supplementary material associated with this article can be found, in the online version, at doi:[10.1016/j.jemermed.2022.04.027](https://doi.org/10.1016/j.jemermed.2022.04.027).

References

1. Ha J, Yu YC, Lannigan F. A review of the management of lymphangiomas. *Curr Pediatr Rev* 2014;10:238–48.
2. Stringer CEA, Sabhaney V, et al. Neck masses in infants and children. In: Tintinalli JE, Ma OJ, Yealy DM, et al, editors. *Tintinalli's emergency medicine: a comprehensive study guide*. New York: McGraw-Hill Education; 2020. p. 782–9.
3. Toye R, Armstrong P, Dacie JE. Lymphangiohaemangioma of the mediastinum. *Br J Radiol* 1991;64:62–4.
4. Riquet M, Brière J, Le Pimpec-Barthes F, Puyo P. Lymphangiohemangioma of the mediastinum. *Ann Thorac Surg* 1997;64:1476–8.
5. Tovichien P, Kaeotawee P, Udomittipong K, Pacharn P, Ruangchira-Urai R. A rare case of mediastinal lymphatic venous malformations in children. *Respirol Case Rep* 2021;9:e0881.
6. Vladimirov PZ, Penka SP, Petrov BI. Lymphangiohemangioma of the anterior mediastinum: case report and literature review. *Eurasian Union of Scientists* 2016;22:96–8.
7. Balbaa A, Chesterman JT. Neoplasms of vascular origin in the mediastinum. *Br J Surg* 1957;44:545–55.
8. Soudack M, Vladovski E, Guralnik L, Ben-Nun A, Engel A. Post-traumatic active bleeding of mediastinal mixed vascular malformation: a case report. *J Pediatr Surg* 2006;41:1316–18.
9. Angtuaco EJ, Jimenez JF, Burrows P, Ferris E. Lymphatic-venous malformation (lymphangiohemangioma) of mediastinum. *J Comput Assist Tomogr* 1983;7:895–7.
10. Williams HJ, Johnson KJ. Imaging of congenital cystic lung lesions. *Paediatr Respir Rev* 2002;3:120–7.