

중이강내 자가 피부이식으로 유도한 실험적 진주종에서 PCNA의 표현 양상

박기현 · 박홍준 · 이원석 · 유영준

Expression of PCNA in Experimental Cholesteatoma by Implanting Autologous Free Skin Graft in Mongolian Gerbil Middle Ear Cavity

Keehyun Park, MD, Hong-Joon Park, MD, Won Seok Lee, MD and Young-Joon Yu, MD

Department of Otolaryngology, Ajou University School of Medicine, Suwon, Korea

ABSTRACT

Background and Objectives : Cholesteatoma in the middle ear is characterized by the presence of a keratinizing epithelium which is believed to have hyperproliferative properties. Among the various approaches for evaluating proliferative activity, proliferating cell nuclear antigen (PCNA) has been recently induced as an antigenic marker of cellular proliferation. In this study, we investigated the hyperproliferative characteristic of implanted skin in Mongolian gerbil middle ear cavity by comparing its mitotic activity with that of the retroauricular skin. A secondary purpose was to provide the morphological basis for future animal studies concerning cholesteatoma pathogenesis. **Materials and Methods** : Using immunohistochemical technique with anti-monoclonal antibody, we investigated PCNA expressions of the implanted free skin and normal retroauricular skin of Mongolian gerbils. **Results** : Experimental cholesteatoma induced by implanting free skin graft showed an average PCNA labeling index of 0.47 ± 0.07 and normal retroauricular skin revealed 0.14 ± 0.05 . The labeling index of experimental cholesteatoma was 3.47 times higher than that of normal retroauricular skin. **Conclusion** : The epithelium of experimental cholesteatoma induced by implanting free skin graft in gerbil middle ear cavity proliferates at a higher rate than its normal retroauricular skin, suggesting that this animal model can be used for future study of epithelial proliferation of cholesteatoma. (Korean J Otolaryngol 1999;42:1098-102)

KEY WORDS : Mongolian gerbil · Autologous free skin graft · PCNA · Immunohistochemistry.

lene glycol) ¹⁾²⁾
, ³⁾⁴⁾
5)
가 ⁶⁾⁷⁾
(chinchilla), PCNA (proliferating cell nuclear antigen)
(rat) gerbil G1
S DNA (DNA
Mongolian gerbil polymerase - auxillary protein) . G1
S G2
M
(propy -
: 1999 4 15 / : 1999 7 16
: , 442 - 749 5
: (0331) 219 - 5266 · : (0331) 219 - 5264
E - mail : parkkh@madang.ajou.ac.kr
가 ⁸⁾⁹⁾ 1993 Uchida ¹⁰⁾
PCNA
Mongolian gerbil

가

PCNA

PCNA L -

, 100%, 90%, 80%, 70%

37 20

, 3%

1 : 10 10

. Blocking rea -

gent(1 : 20 horse serum) 30 1 : 50

PCNA anti - mouse monoclonal anti -

body(PC 10 ; Novocastra Lab., U.K.) 4

. TBS anti - mouse biotinylated

IgG(DAKO Co., Denmark) 2 30

, ABC(avidin - biotin peroxidase complex ;

DAKO Co., Denmark) 30

AEC(3 - amino - 9 - ethylcarbazole ; DAKO Co., Den -

mark) , Mayer hematoxylin

Mongolian gerbil의 중이강내 자가 피부이식

Mongolian gerbil xylazine(; Rompun,

; 8 mg/kg) ketamine hydrochloride(; Ke -

talar, ; 40 mg/kg)

. pick

Mon -

golian gerbil 0.5 × 0.5 cm , 5

. PCNA

PCNA

PCNA

PCNA = $\frac{\text{PCNA}}{\text{PCNA}}$

50 cc

10% 100 cc , t - te -

. Mongolian gerbil st

Mongolian gerbil

10%

3 5% EDTA(ethylene diamine tetraac -

etic acid) 3 가

10 Mo -

5 μm ngolian gerbil, 20 3

15 75% . 15

면역조직화학적 염색방법 3 가 ,

12 PCNA

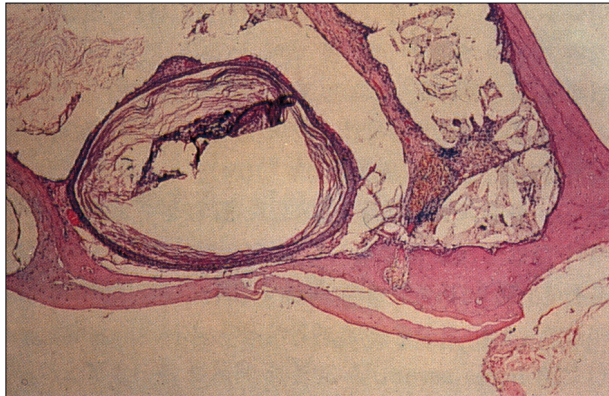


Fig. 1. Light microscopic finding of implanted skin : The skin graft is well taken with accumulation of keratin debris (H & E stain, $\times 40$).

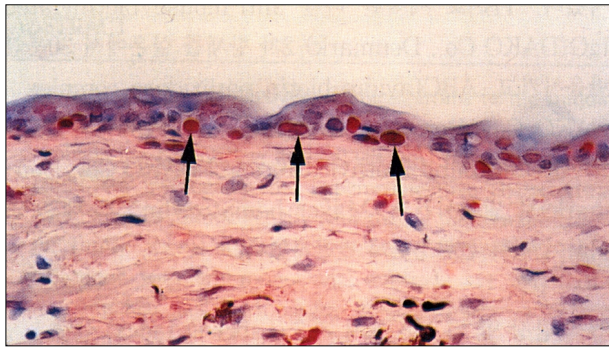


Fig. 2. Immunostaining of normal retroauricular skin : PCNA-positive cells (arrows) are mainly observed in basal layer of the epithelium (ABC immunostain, $\times 400$).

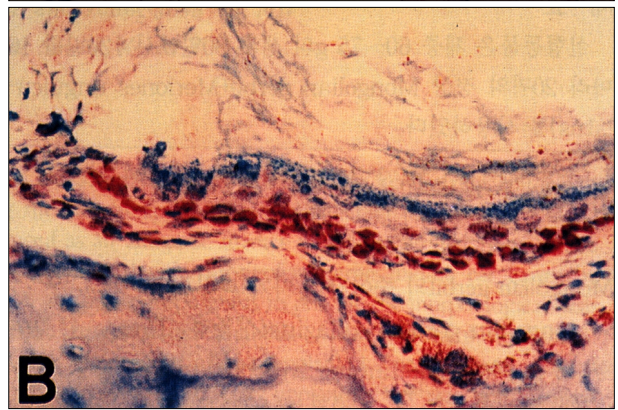
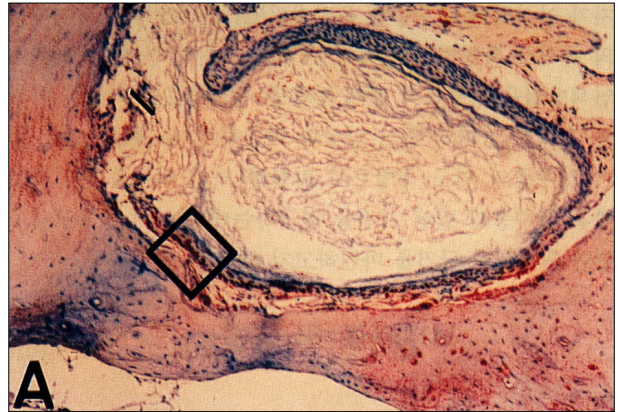


Fig. 3. Immunostaining of implanted skin. A : Skin attached-area shows PCNA-positive staining (ABC immunostain, $\times 100$). B : Rectangle shows many PCNA-positive cells in the basal and suprabasal keratinocytes (ABC immunostain, $\times 400$).

Species	Sample	PCNA	LI
Mongolian gerbil	가	가	0.31
	가	가	0.55
Implanted Skin	가	가	0.47 ± 0.07
	가	가	0.14 ± 0.05

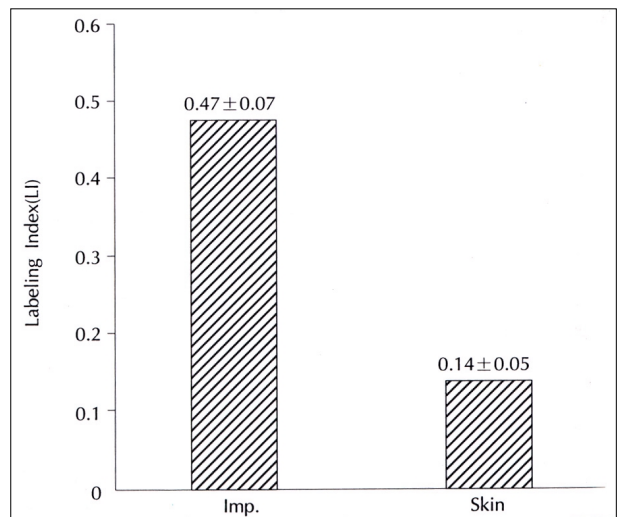


Fig. 4. Labeling index (LI) of implanted skin and normal retroauricular skin. LI of implanted skin is statistically higher than that of normal retroauricular skin ($p < 0.01$). Imp. : Implanted Skin, Skin : Retroauricular Skin

PCNA
 PCNA (p 0.01)(Fig. 4).
 PCNA 가 , 가
 가 가 ,
 PCNA 가
 , Bujia ¹⁵⁾
 (epidermal growth
 factor - receptor)
 가 PCNA
 가 ⁹⁾¹⁵⁾
 ,
 가 .
 PCNA 가
 가 ,
 .
¹¹⁾
 가
 PCNA 가
 가 Chang ¹⁶⁾
 Park ¹⁷⁾
 .
 가 .
 Ottaviani ¹⁸⁾ tritium - thymidine
 가 2.8 가
 , Chang ¹⁶⁾
 3.24 가
 .
 Mongolian gerbil
¹³⁾ McGinn Chole⁴⁾ Mongolian
 gerbil
 , Wolfman Chole⁵⁾ Mongolian gerbil
 (retraction pocket)가
 . Wright ²⁾ cortisporin
 , Vassalli ¹⁾
 .
 Hinohira ⁷⁾
 가
 .
 (dysregulation)
 가 가 가
 , TGF- (transforming
 growth factor -), GM - CSF(granulocyte - macrophage
 colony stimulating factor), IL - 1(interleukin - 1)
 TNF - (tumor necrosis factor -)
 (growth factor) 가가
 .¹⁵⁾
 가
 .
 PCNA 가 가 ,
 Ki - 67 bromodeoxyuridine
 .¹⁴⁾ PCNA 가 가
 .
 G1 S DNA 가
 . G1 S Mo -
 G2 M . ngolian gerbil 가
 가
 , 가
 .⁸⁾⁹⁾ Mongolian gerbil
 .
 PCNA .

Mongolian gerbil 가
 PCNA 가 가 ,
 가
 , Mongolian gerbil
 : Mongolian gerbil . 가 . PCNA .

REFERENCES

- 1) Vassalli L, Harris DM, Gradini R, Applebaum E. *Propylene glycol-induced cholesteatoma in chinchilla middle ear. Am J Otolaryngol* 1988;9:180-8.
- 2) Wright CG, Meyerhoff WL, Burns DK. *Middle ear cholesteatoma: An animal model. Am J Otolaryngol* 1985;6:327-34.
- 3) Park K, Park HJ, Chun YM. *Experimentally induced aural cholesteatoma in Gerbil. Korean J Otolaryngol* 1995;38:330-3.
- 4) McGinn MD, Chole RA. *Cholesteatoma: Experimental induction in the Mongolian gerbil, Meriones unguiculatus. Acta Otolaryngol (Stockh)* 1982;93:61-7.
- 5) Wolfman DE, Chole RA. *Experimental retraction pocket cholesteatoma. Ann Otol Rhinol Laryngol* 1986;95:639-44.
- 6) Park K, Chun YM, Kim SM, Lee DH. *Experimental cholesteatoma by transplanting a free skin graft in the bulla of mongolian gerbil. Korean J Otolaryngol* 1996;39:1138-43.
- 7) Hinohira Y, Gyo K, Yanagihara N. *Experimental cholesteatoma arising from autologous free skin grafting in the middle ear cavity. Acta Otolaryngol (Stockh)* 1994;114:533-8.
- 8) Bravo R, Frank R, Blundell PA, Macdonald-Bravo H. *Cyclin /PCNA is the auxillary protein of DNA polymerase-δ . Nature* 1987;326:515-7.
- 9) Prelich G, Tan CK, Kostura M, Mathews MB, So AG, Downey KM, et al. *Functional identity of proliferating cell nuclear antigen and a DNA polymerase-δ auxillary protein. Nature* 1987;326:517-20.
- 10) Uchida N, Ito S, Hirano M. *Localization of proliferating cell nuclear antigen in aural cholesteatoma. The Kurume Med J* 1993;40:225-8.
- 11) Jackson D, Lim D. *Fine morphology of the advancing front of cholesteatoma: Experimental and human. Acta Otolaryngol (Stockh)* 1978;86:71-88.
- 12) Kim HJ, Chole RA. *Experimental models of aural cholesteatomas in Mongolian gerbils. Ann Otol Rhinol Laryngol* 1998;107:129-34.
- 13) Chole RA, Henry KP, McGinn MD. *Cholesteatoma: Spontaneous occurrence in the Mongolian gerbil, meriones unguiculatus. Am J Otol* 1981;2:204-10.
- 14) Koba R. *Epidermal cell migration and healing of the tympanic membrane: An immunohistochemical study of cell proliferation using bromodeoxyuridine labeling. Ann Otol Rhinol Laryngol* 1995;104:218-25.
- 15) Bujia J, Holly A, Schilling V, Negri B, Pitzke P, Schulz P. *Aberrant expression of epidermal growth factor receptor in aural cholesteatoma. Laryngoscope* 1993;103:326-9.
- 16) Chang KH, Cho HC, Hwang CS, Yang HS, Kim CG, Park ES. *Expression of PCNA in Cholesteatoma and Auditory Meatal Skin. Korean J Oto-laryngol* 1996;39:1832-8.
- 17) Park K, Chun YM. *Immunohistochemical detection of proliferating cell nuclear antigen in experimental cholesteatoma. Proc Sendai Ear Symposium* 1996;6:125-7.
- 18) Ottaviani F, Sambataro G, Mantovani M, Lavezzi AM, Matturri L. *Middle ear cholesteatoma: A cytodagnostic study of cellular proliferative activity. In: Tos M, Thomsen, Peitertsen E, editors. Cholesteatoma and mastoid surgery. Proceedings of the third Conference on Cholesteatoma and Mastoid surgery;1988 June 5-9;Copenhagen, Denmark. Amsterdam: Kugler & Ghedini; 1989. p.119-24.*