

## Temporary Placement of a Newly Designed, Fully Covered, Self-Expandable Metal Stent for Refractory Bile Leaks

Jae Chul Hwang\*, Jin Hong Kim\*, Byung Moo Yoo\*, Sun-Gyo Lim\*, Jin Hun Kim<sup>†</sup>, Wook Hwan Kim<sup>†</sup>, and Myung Wook Kim<sup>†</sup>

Departments of \*Gastroenterology and <sup>†</sup>Surgery, Ajou University School of Medicine, Suwon, Korea

Bile leaks remain a significant cause of morbidity for patients undergoing laparoscopic cholecystectomy. Leakage from an injured duct of Luschka (subvesical duct) follows the cystic duct as the most common cause of postcholecystectomy bile leaks. Although endoscopic sphincterotomy, plastic-stent placement, or nasobiliary-drain placement are effective in healing biliary leaks, in patients in whom leakage persists and the symptoms worsen despite conventional endoscopic treatment, re-exploration with laparoscopy and ligation of the injured subvesical duct should be considered. We present herein the case of a 31-year-old woman with refractory bile leakage from a disrupted subvesical duct after cholecystectomy that could not be managed with endoscopic sphincterotomy and plastic-stent placement. A newly designed, fully covered, self-expandable metal stent (FC-SEMS) was successfully placed for the treatment of refractory bile leaks in this patient. It appears that temporary placement of an FC-SEMS is technically feasible and provides an effective alternative to surgical therapy for refractory bile leaks after cholecystectomy. (**Gut Liver 2011;5:96-99**)

**Key Words:** Bile leak; Self-expandable metal stent; Duct of Luschka; Laparoscopic cholecystectomy

### INTRODUCTION

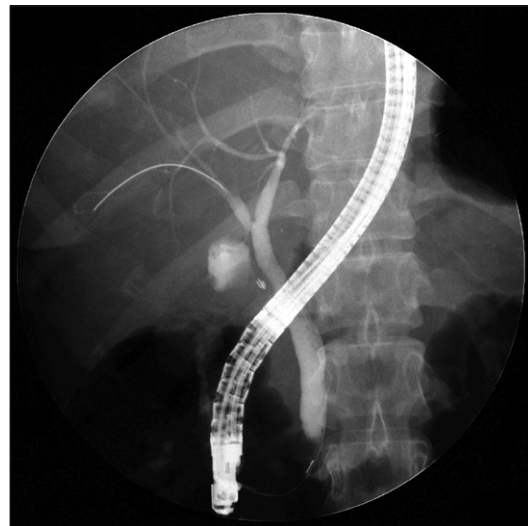
Bile leaks occur in 0.2-2% of patients undergoing laparoscopic cholecystectomy;<sup>1</sup> injury to the duct of Luschka (subvesical duct) is a relatively frequent cause of such leaks. Several endoscopic approaches for the management of symptomatic postoperative bile leaks are now well established, including biliary sphincterotomy alone, plastic stent placement with or without sphincterotomy, and sphincterotomy followed by nasobiliary tube placement.<sup>2,3</sup> However, large or complex bile leaks require the placement of multiple large stents that cover the bile leak,

and surgery may still required.<sup>4</sup>

In this report, we present our experience using a newly designed, fully covered, self-expandable metal stent (FC-SEMS) for the treatment of bile leaks from the subvesical duct in a patient whose general condition worsened and ongoing leakage persisted despite conventional endoscopic treatment.

### CASE REPORT

A 31-year-old woman was admitted with severe abdominal pain and a fever 5 days after undergoing laparoscopic cholecystectomy for the management of acute cholecystitis. Abdominal computed tomography (CT) revealed a small amount of fluid collection in the perihepatic space, the porta hepatis region, and the pelvic cavity. An endoscopic retrograde cholangiopancreatography (ERCP) was performed for suspected postoperative



**Fig. 1.** Cholangiogram showing a leak originating at the duct of Luschka that drains to the right hepatic duct.

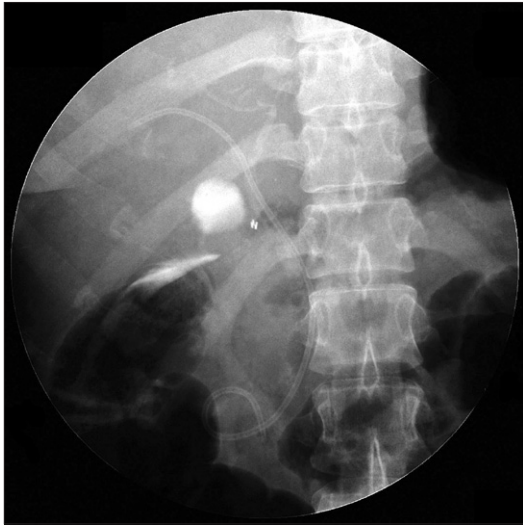Correspondence to: Jin Hong Kim

Department of Gastroenterology, Ajou University School of Medicine, San-5, Woncheon-dong, Yeongtong-gu, Suwon 442-721, Korea

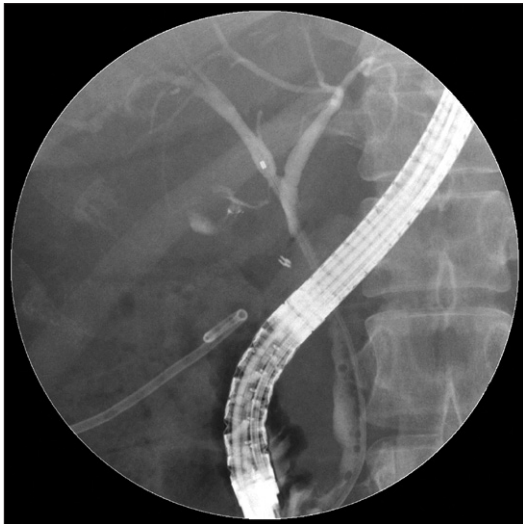Tel: +82-31-219-6937, Fax: +82-31-219-5999, E-mail: jinhkim@ajou.ac.kr

Received on February 9, 2010. Accepted on March 30, 2010.

pISSN 1976-2283 eISSN 2005-1212 DOI: 10.5009/gnl.2011.5.1.96



**Fig. 2.** Fluoroscopic image showing a double-pigtail stent in place after endoscopic sphincterotomy.



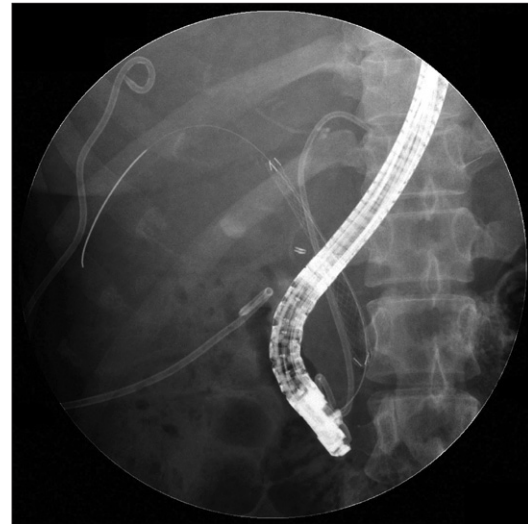
**Fig. 3.** Cholangiogram showing persistent leakage from the same site and a pigtail catheter for evacuating the peritoneal fluid.

bile leakage, revealing bile leaking through the right hepatic duct from the disrupted duct of Luschka at the liver bed into the subhepatic space where the gallbladder originally existed (Fig. 1). A 7-Fr, 10-cm double pigtail plastic stent was placed in the bile duct after endoscopic sphincterotomy (Fig. 2), and the patient was given a broad-spectrum antibiotic and observed. She continued to have a high fever reaching 39.5°C with a rising C-reactive protein. An abdominal CT performed 2 days after ERCP showed an increased amount of fluid collection in the abdominal cavity. The abdomen was distended and diffusely tender upon abdominal palpation. Although two percutaneous drainage catheters were inserted to drain the fluid from the abdominal cavity, the symptoms worsened. A second ERCP revealed continued bile leakage from the same site (Fig. 3).

We decided to use a FC-SEMS for the treatment of the sus-



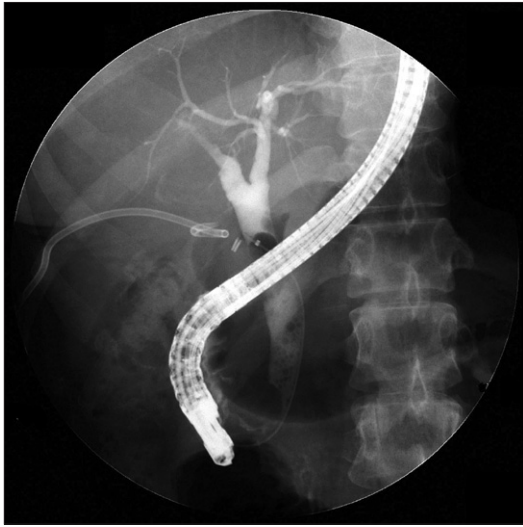**Fig. 4.** A retrievable polytetrafluoroethylene-covered, self-expandable metal stent with a ball-tipped distal end.



**Fig. 5.** Insertion of the fully covered, self-expandable metal stent into the right hepatic duct after deployment of a 7-Fr double-pigtail stent into the left intrahepatic duct.

tained leakage. The stent used in this patient was a newly developed, retrievable polytetrafluoroethylene (PTFE)-FC-SEMS with a ball-type wire mesh at the distal end (Bumpy stent, diameter 10 mm; Taewoong Medical, Seoul, Korea), which was designed for anti-migration and anti-reflux (Fig. 4). After placement of a 7-Fr double pigtail plastic stent in the left intrahepatic duct for the prevention of blockage by the covering of the FC-SEMS, the 6-cm FC-SEMS was deployed in the right hepatic duct for direct blockage of the orifice of the duct of Luschka with the distal end inside the common bile duct (Fig. 5).

Following stent placement, the amount of fluid drained from the percutaneous catheters decreased immediately and her symptoms and general condition rapidly improved. There was no migration of the FC-SEMS in the right hepatic duct until its removal 28 days after placement. The ball-tipped end of the FC-SEMS was easily grasped using rat-tooth forceps under fluoro-



**Fig. 6.** Cholangiogram after removal of the stents showing closure of the leak.

scopic guidance, and the stent was successfully removed without any complications. Following that, the plastic stent in the left intrahepatic bile duct was also removed. A cholangiogram revealed successful closure of the bile leakage from the duct of Luschka (Fig. 6). She remained well with no biliary symptoms at the 5-month follow-up.

## DISCUSSION

Laparoscopic cholecystectomy has become the procedure of choice for symptomatic cholelithiasis. Although this technique is associated with decreased mortality and length of hospital stay, some complications, such as bile leaks, are more common than after open cholecystectomy.<sup>5</sup> Bile leaks usually arise during the first week after surgery and present with abdominal pain, fever, and tenderness.<sup>6</sup> Subvesical duct leaks follow the cystic duct as the most common cause of postcholecystectomy bile leaks.<sup>7</sup> The duct of Luschka mostly drains into the right and common hepatic ducts, and less frequently drains into the subsegmental ducts, sectoral ducts, and left hepatic duct.<sup>8</sup> The amount of bile that extravasates after a subvesical duct injury is variable. If the injured end is connected with the central biliary tree, the volume of extravasated bile may be high. Conventional endoscopic treatment with sphincterotomy, plastic stent placement, or nasobiliary tube placement will lower the pressure gradient between the biliary tree and the duodenum with preferential bile flow through the papilla, leading to closure of the leak.<sup>9,10</sup> Endoscopic stenting usually plays a role in tamponading the leak site with the proximal tip of the stent above the leak site, which may be useful in certain cases.<sup>11</sup> However, in patients in whom leakage continues and the symptoms worsen despite conventional endoscopic treatment, re-exploration with laparoscopy and ligation of the injured subvesical duct should be considered.<sup>7</sup>

In the case of the patient presented herein, who had severe symptoms and continuing leakage despite conventional endoscopic treatment with endoscopic sphincterotomy and plastic stent placement, a retrievable FC-SEMS was used for the treatment of bile leaks from the duct of Luschka instead of re-exploration with laparoscopy. The placement of a FC-SEMS is more effective in the immediate blocking of biliary leaks because of its larger diameter than plastic stents.<sup>12</sup> Biliary metal stents have recently been used to maintain ductal patency in patients with benign biliary strictures.<sup>13-15</sup> However, the use of an uncovered SEMS for benign biliary strictures is highly controversial because they are associated with epithelial hyperplasia, leading to chronic inflammation and becoming embedded in the bile duct wall.<sup>15,16</sup> Temporary placement of covered SEMSs for benign biliary strictures may offer an alternative to plastic stenting, but is associated with migration.<sup>15</sup> Wang *et al.*<sup>4</sup> reported temporary placement of FC-SEMSs was efficacious at resolving both complex intra- and extra-hepatic bile leaks in 13 patients. Of these patients, 10 had *de novo* choledocholithiasis or debris within the FC-SEMS and common bile duct at the time of stent removal. In five of seven patients who underwent choledochoscopy, mucosal ulcerations of the bile duct were noted following FC-SEMS removal, which may be due to the fins of the stent that are intended to prevent stent migration. The stent used in this patient was a newly developed FC-SEMS which was designed for anti-migration and anti-reflux. The wire mesh is made of uneven woven segments, which produces a different radial force and is the basis for the anti-migration properties. The ball-type wire mesh at the distal end was originally designed to prevent reflux of the duodenal contents into the biliary tract. In this case, a shorter FC-SEMS was placed in the common bile duct without crossing the duodenal ampulla because long FC-SEMSs are not commercially available, but it could easily be grasped and removed with rat-tooth forceps inside of the bile duct only under fluoroscopic guidance due to its ball-tipped end, even though its distal end is in the common bile duct and cannot be seen under endoscopic vision. In addition, a common complication of FC-SEMS placement is *de novo* choledocholithiasis and/or luminal debris, which is probably due to food debris and bacteria that migrate into the FC-SEMS and bile duct as a result of duodenal biliary reflux when the FC-SEMS is crossed over the papilla and into the duodenum.<sup>4</sup> This complication did not occur after stent removal in our case. Therefore, the shorter FC-SEMS placement without crossing the duodenal ampulla seems to be effective in preventing this complication.

Reportedly, the time required for closure of a bile leak after placing a stent or nasobiliary drain is 1-7 days.<sup>9</sup> However, the success rates are more variable in cases of more complicated leaks associated with significant bile duct injuries, and the required period of biliary stenting is prolonged beyond the time required for sole leak closure.<sup>9</sup> Thus, in this case, in which leakage continued and the symptoms worsened despite conventional

endoscopic treatment, we left the stent in place for a prolonged period of 4 weeks.

In summary, temporary placement of a FC-SEMS seems to be a feasible and effective alternative in patients who have failed resolution of their leak, despite plastic stent placement after cholecystectomy. Further studies need to be conducted, aimed at confirming the safety and efficacy in patients with refractory postoperative bile leaks.

## REFERENCES

1. Albasini JL, Aledo VS, Dexter SP, Marton J, Martin IG, McMahon MJ. Bile leakage following laparoscopic cholecystectomy. *Surg Endosc* 1995;9:1274-1278.
2. Davids PH, Rauws EA, Tytgat GN, Huibregtse K. Postoperative bile leakage: endoscopic management. *Gut* 1992;33:1118-1122.
3. Chow S, Bosco JJ, Heiss FW, Shea JA, Qaseem T, Howell D. Successful treatment of post-cholecystectomy bile leaks using nasobiliary tube drainage and sphincterotomy. *Am J Gastroenterol* 1997;92:1839-1843.
4. Wang AY, Ellen K, Berg CL, Schmitt TM, Kahaleh M. Fully covered self-expandable metallic stents in the management of complex biliary leaks: preliminary data - a case series. *Endoscopy* 2009;41:781-786.
5. Sandha GS, Bourke MJ, Haber GB, Kortan PP. Endoscopic therapy for bile leak based on a new classification: results in 207 patients. *Gastrointest Endosc* 2004;60:567-574.
6. Barkun AN, Rezieg M, Mehta SN, et al. Postcholecystectomy biliary leaks in the laparoscopic era: risk factors, presentation, and management. McGill Gallstone Treatment Group. *Gastrointest Endosc* 1997;45:277-282.
7. Mergener K, Strobel JC, Suhocki P, et al. The role of ERCP in diagnosis and management of accessory bile duct leaks after cholecystectomy. *Gastrointest Endosc* 1999;50:527-531.
8. Kitami M, Murakami G, Suzuki D, et al. Heterogeneity of subvesical ducts or the ducts of Luschka: a study using drip-infusion cholangiography-computed tomography in patients and cadaver specimens. *World J Surg* 2005;29:217-223.
9. Mehta SN, Pavone E, Barkun JS, Cortas GA, Barkun AN. A review of the management of post-cholecystectomy biliary leaks during the laparoscopic era. *Am J Gastroenterol* 1997;92:1262-1267.
10. Foutch PG, Harlan JR, Hoefler M. Endoscopic therapy for patients with a post-operative biliary leak. *Gastrointest Endosc* 1993;39:416-421.
11. Smith AC, Schapiro RH, Kelsey PB, Warshaw AL. Successful treatment of nonhealing biliary-cutaneous fistulas with biliary stents. *Gastroenterology* 1986;90:764-769.
12. Kahaleh M, Sundaram V, Condron SL, et al. Temporary placement of covered self-expandable metallic stents in patients with biliary leak: midterm evaluation of a pilot study. *Gastrointest Endosc* 2007;66:52-59.
13. Cantu P, Hookey LC, Morales A, Le Moine O, Deviere J. The treatment of patients with symptomatic common bile duct stenosis secondary to chronic pancreatitis using partially covered metal stents: a pilot study. *Endoscopy* 2005;37:735-739.
14. Kahaleh M, Behm B, Clarke BW, et al. Temporary placement of covered self-expandable metal stents in benign biliary strictures: a new paradigm? (with video). *Gastrointest Endosc* 2008;67:446-454.
15. Mahajan A, Ho H, Sauer B, et al. Temporary placement of fully covered self-expandable metal stents in benign biliary strictures: midterm evaluation (with video). *Gastrointest Endosc* 2009;70:303-309.
16. Kahaleh M, Tokar J, Le T, Yeaton P. Removal of self-expandable metallic Wallstents. *Gastrointest Endosc* 2004;60:640-644.