

## LETTER TO THE EDITOR

# Molluscum Contagiosum Presenting as a Cutaneous Horn

Ji Hyun Sim, M.D., Eun-So Lee, M.D.

Department of Dermatology, Ajou University School of Medicine, Suwon, Korea

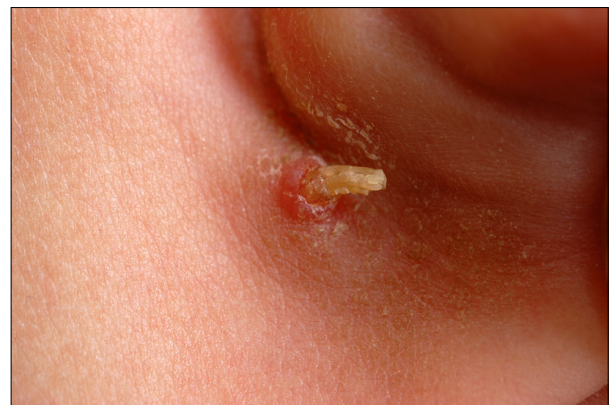Dear Editor:

A 9-year-old girl presented with asymptomatic, rapidly growing, papular lesions in the posterior auricular area since the past 2 months. The medical history was non-contributory. There was no history of blood transfusion and no family history of HIV infection. No previous history of trauma or inflammation in the lesions was noted. The physical examination revealed a hyperkeratotic projection on the umbilicated papule in the posterior auricular area (Fig. 1). Under the clinical diagnosis of a cutaneous horn, a skin biopsy was performed and it revealed hyperkeratosis and an acanthotic epidermis with craters on low-power view of the skin specimen (Fig. 2A). Under high-power magnification, many epidermal cells were shown to contain eosinophilic hyaline intracytoplasmic inclusion bodies, which are the hallmarks of molluscum contagiosum (MC). The molluscum bodies increased in size as the infected cells moved toward the surface (Fig. 2B). The lesion was totally removed by skin biopsy and after 3 months follow-up, no recurrence was observed.

MC is a poxvirus infection, occurring generally in children, but it may be found in people of all ages. Incidence of MC has risen significantly by up to 20% worldwide with the trend increasing in the United States and immunocompromised children such as HIV and leukemia patients are more commonly affected with MC<sup>1</sup>. MC lesions consists of papular eruptions of multiple, umbilicated lesions which are variable in number. The papules are small, discrete, waxy, skin-colored, dome-shaped, and usually 2~5 mm in size. The lesions of MC that occur in patients with HIV exhibit an extensive

pattern with atypical morphology, such as giant molluscum, molluscum presenting as an abscess, molluscum without any umbilication, tender molluscum, and erythematous nodular types<sup>2</sup>. A cutaneous horn is the clinical description of a white or yellow, short or curved, dense protrusion from the skin surface consisting of cornified material. The important issue is not the horn itself, which is dead keratin, but rather the underlying condition. Cutaneous horns may be benign, like seborrheic keratosis and viral warts. However, approximately 50% of cutaneous horns arise from either premalignant (actinic keratosis and Bowen's disease) or malignant lesions (squamous cell carcinoma), thus an accurate diagnosis of the underlying disease is essential and an adequate amount of material from the base of the lesion is necessary to confirm the diagnosis<sup>3</sup>.

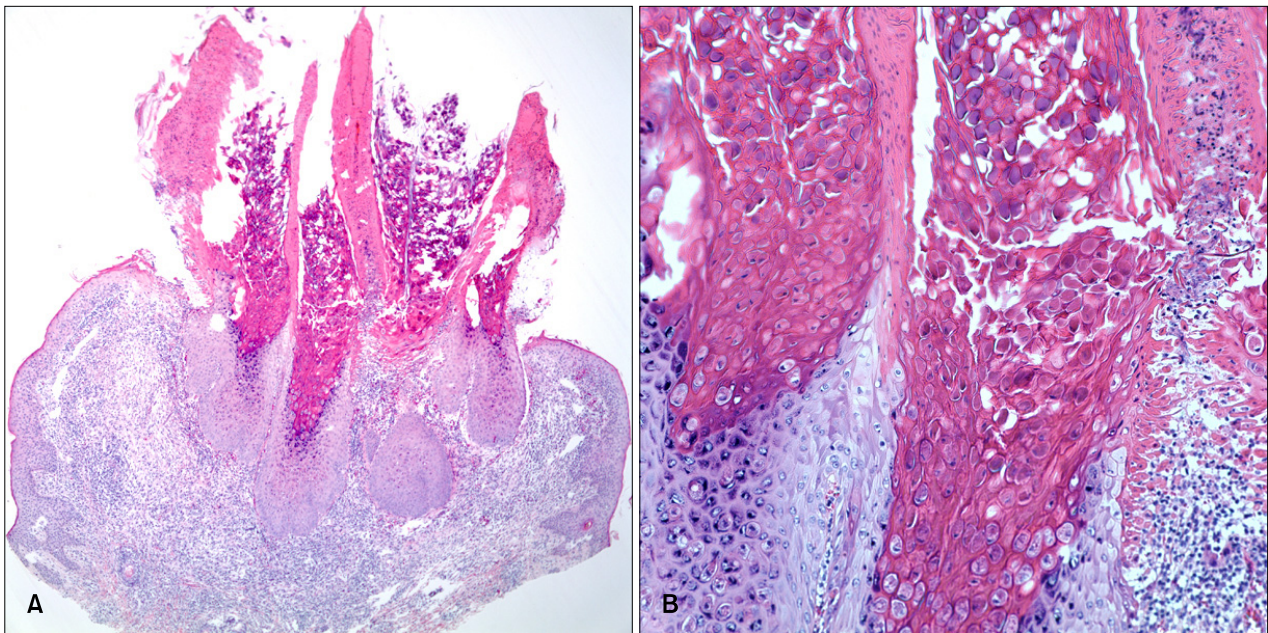
MC presenting as a cutaneous horn has previously been reported as a penile horn in two adults and as a solitary firm horn-like projection on the left upper eyelid in one child. They all were HIV-positive<sup>3-5</sup>. This is an interesting case of MC presenting as a cutaneous horn in an immunocompetent patient. Therefore in an effort to establish an early diagnosis of MC, clinicians should be aware of



**Fig. 1.** Hyperkeratotic projection on the umbilicated papule in the posterior auricular area.

Received May 18, 2010, Revised June 10, 2010, Accepted for publication June 10, 2010

**Corresponding author:** Eun-So Lee, M.D., Department of Dermatology, Ajou University School of Medicine, San 5 Wonchon-dong, Yeongtong-gu, Suwon 443-721, Korea. Tel: 82-31-219-5190, Fax: 82-31-219-5189, E-mail: esl@ajou.ac.kr



**Fig. 2.** (A) Hyperkeratosis and acanthotic epidermis with craters (H&E,  $\times 40$ ). (B) Under high-power magnification, many epidermal cells were shown to contain eosinophilic hyaline intracytoplasmic inclusion bodies, which are the hallmarks of molluscum contagiosum (H&E,  $\times 200$ ).

such cases.

## REFERENCES

1. Brown J, Janniger CK, Schwartz RA, Silverberg NB. Childhood molluscum contagiosum. *Int J Dermatol* 2006;45:93-99.
2. Sen S, Goswami BK, Karjyi N, Bhaumik P. Disfiguring molluscum contagiosum in a HIV-positive patient responding to antiretroviral therapy. *Indian J Dermatol* 2009; 54:180-182.
3. Schwartz JJ, Myskowski PL. HIV-related molluscum contagiosum presenting as a cutaneous horn. *Int J Dermatol* 1992;31:142-144.
4. Manchanda Y, Sethuraman G, Paderwani PP, Singh M, Singh MK. Molluscum contagiosum presenting as penile horn in an HIV positive patient. *Sex Transm Infect* 2005;81:183-184.
5. Thappa DM, Laxmisha C. Cutaneous horn of eyelid. *Indian Pediatr* 2004;41:195.