

A Floppy Baby with Congenital Myotonic Dystrophy Complicated with Huge Subgaleal Hematoma Occurring in Non-instrumental Vaginal Delivery

Shin-Young Yim · Kye Hee Cho · Jae-Young Kim · Ji-Yeon Hong · Il Yung Lee

Department of Physical Medicine and Rehabilitation, Ajou University School of Medicine, Suwon, Korea

Not only is the concurrence of congenital myotonic dystrophy (CDM) and subgaleal hematoma (SGH) hardly ever seen but also the development of SGH during unassisted vaginal delivery is rare. We report a boy who developed huge SGH in vaginal delivery without any use of vacuum or forceps and later was diagnosed as maternally transmitted CDM. The boy had prenatal history of polyhydramnios and decreased fetal movement. Six hours after birth, severe molding of the skull associated with huge SGH on left parieto-occipital area was recognized by CT scan. At corrected age of two months, he was diagnosed as maternally transmitted CDM. This is the first report of CDM complicated by SGH occurring in non-instrumental vaginal delivery.

Key Words: Congenital Myotonic dystrophy, Hematoma, Vacuum Extraction

Introduction

Myotonic dystrophy type 1 (DM1) is one of the non-coding triplet repeats expansion disorders, causing a typical disease features such as myotonia and progressive muscle weakness. Neonates with congenital myotonic dystrophy type 1 (CDM) most commonly involves hypotonia, respiratory distress, and/or feeding difficulties, unlike the characteristic features of adult onset DM1¹⁾. It is well known that the obstetric complications are significantly increased in women with

DM1²⁾. The typical neonatal symptoms of CDM are frequently misunderstood as the sequelae of obstetric and/or perinatal complications, leading to belated diagnosis of CDM.

Subgaleal hematoma (SGH) is not common but often occurs as the result of birth trauma related to instrumental delivery using vacuum and/or forceps or coagulopathies³⁾. Not only is the concurrence of CDM and SGH rare but also SGH developed in unassisted vaginal delivery seldom occurs. We report a boy with huge SGH, who was vaginally delivered without any use of vacuum or forceps and later diagnosed as maternally transmitted CDM.

Case report

This was the exempted case from the review of Institutional Research Board of Ajou University Medical Center. The boy was the product of in-vitro fertilization

접 수: 2009년 11월 26일

수정본접수: 2009년 12월 9일

게재승인일: 2009년 12월 11일

게재일: 2009년 12월 31일

Corresponding author: Shin-Young Yim

Department of Physical Medicine and Rehabilitation, Ajou University School of Medicine, San 5 Woncheon-dong, Youngtong-Ku, Suwon, 442-749, Korea

Tel: +82-31-219-5802, Fax: +82-31-219-5209

E-mail: syyim@ajou.ac.kr

between 25 year-old mother and 30 year-old father. The obstetric history of the mother was gravida 2 with a missed abortion at 7 weeks. Due to a traumatic anal perforation in her childhood, she had a large abdominal scar from colostomy. Although polyhydramnios and decreased fetal movement were reported during pregnancy, her colostomy-related scar made her obstetrician prefer vaginal delivery to Cesarean section. At 37 weeks of gestation after rupture of membrane, the boy was born by vaginal delivery with the birth weight of 2,870 gram. APGAR score at one and five minutes were 7 and 8, respectively. Owing to large postpartum hemorrhage, the mother had to receive three pints of blood transfusion. Six hours after birth, severe molding of the skull was revealed with 80% of oxygen saturation. The brain CT scan taken showed huge SGH on left

parieto-occipital area along with subdural hemorrhage at the tentorial edge and small intraventricular hemorrhage in the occipital horn of right lateral ventricle (Fig. 1). The brain MRI taken after one week still showed large SGH on left parieto-occipital area with petechial hemorrhage on bilateral frontal area and periventricular white matter (Fig. 1). The blood test on the first day showed normal coagulation profile with 11.5 seconds of prothrombin time (PT; reference value 10.2–13.8 seconds) and 43 seconds of activated partial thromboplastin time (aPTT; reference value 31.3–54.5 seconds). The mother also showed no evidence of coagulopathy with 11.8 seconds of PT (reference value 10.2–13.8 seconds) and 26 seconds of aPTT (reference value 25–37 seconds).

At corrected age of two months, he was referred to

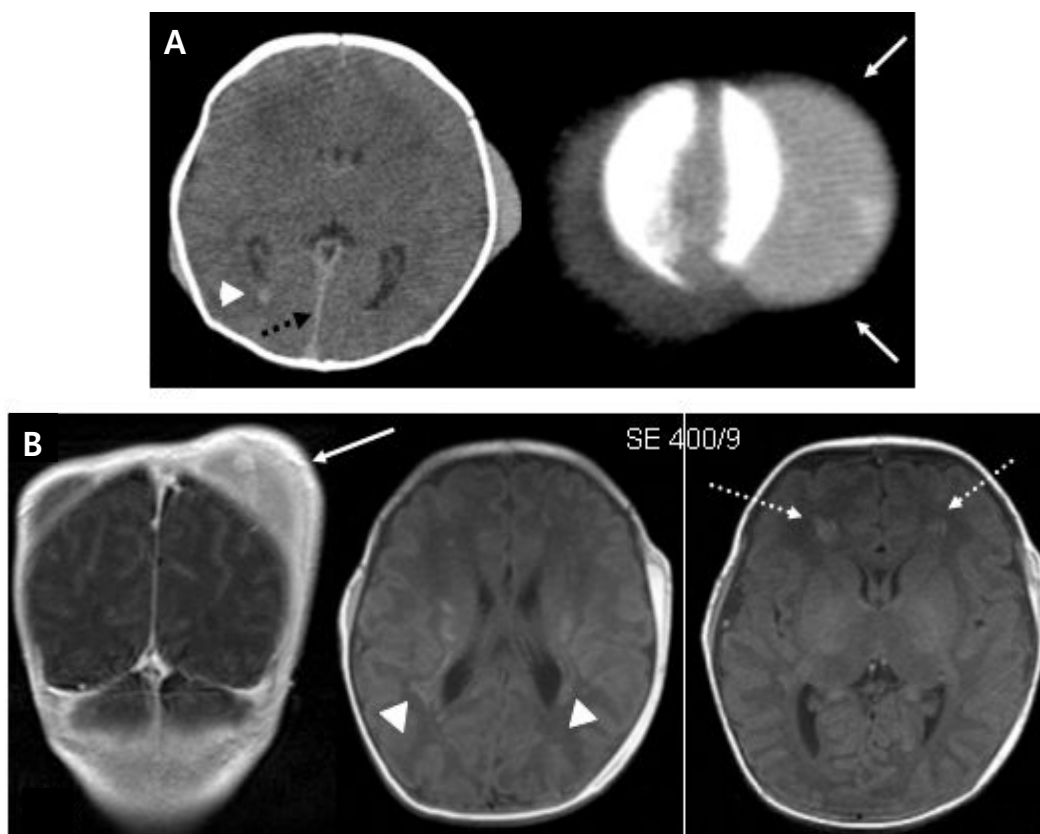


Fig. 1. The radiologic findings showing subgaleal hematoma (SGH). (A) The brain CT scan reveals huge SGH on left parieto-occipital area (arrow) along with subdural hemorrhage at the tentorial edge (dotted arrow) and small intraventricular hemorrhage in the occipital horn of right lateral ventricle (arrowhead). (B) Brain MRI at the age of 7 days shows huge subgaleal hematoma on left parieto-occipital area (arrow), hemorrhage at the bilateral frontal area (dotted arrow) and periventricular white matter (arrowhead).

our department for hypotonia. He was extremely floppy with the absence of all deep tendon reflexes and showed significant generalized weakness. His sucking was too weak that it needed extra time to feed him. His mother had a long face with temporal wasting and reported very poor athletic and academic performance as a student. On physical examination, mild muscle weakness more profound in the distal than the proximal muscles was recognized. She also had difficulty with relaxation (myotonia). Needle electromyography of the limb musculature disclosed the classic waxing–waning “dive–bomber” myotonic discharges. As with the history of learning difficulties, an IQ test revealed intellectual disability of total IQ 69. The diagnosis of myotonic dystrophy was confirmed by Southern blotting for CTG repeats in the 3' UTR of the myotonic–protein kinase gene of chromosome 19 for the baby and his parents. The child had one normal allele with 5 CTG repeats and second allele with large expansion of more than 1,000 CTG repeats ($5/\geq 1,000$). The number of CTG repeats in the mother was $12/\geq 1,000$, whereas the father had normal sized CTG repeats of 5/13. These findings confirmed that he had maternally transmitted CDM. The results of ECG and ophthalmologic evaluation were normal for both the mother and the boy.

Discussion

We have reported a boy who developed huge SGH during non–instrumental vaginal delivery without any use of vacuum or forceps, and after two months was diagnosed as maternally transmitted CDM. Not only is the concurrence of CDM and SGH hardly ever seen but also the development of SGH during unassisted vaginal delivery is rare. The most common findings of brain MRI in CDM involves some degree of ventricular dilatation, white matter lesion at the postero–superior trigon, cortical atrophy, and hypoplasia of corpus callosum⁴⁾. According to the literature review, there was only one case report of SGH in CDM, where a 5–year–old Taiwan

girl was referred for developmental delay and learning difficulty. She was born at full term via vacuum–assisted vaginal delivery. As a neonate, she suffered from SGH along with subarachnoid hemorrhage and small intraventricular hemorrhage on right lateral ventricle. Although her perinatal history disclosed polyhydramnios and hypotonia, it was not until 5 years of age that the final diagnosis of maternally inherited CDM was made. Moreover, the SGH in this case was the product of vacuum extraction and neither any picture nor details regarding the location or severity of the SGH were provided⁵⁾.

SGH develops when blood collects in the loose areolar tissue between the periosteum of the skull and the galea aponeurotica when the emissary veins are severed with intense shearing forces applied to the scalp. Large number of SGH is associated intracranial hemorrhage, including subarachnoid hemorrhage, intraventricular hemorrhage, intraparenchymal hemorrhage, and subdural hemorrhage. Most cases of neonatal SGH have been associated with instrumental delivery using vacuum and/or forceps. Neonatal SGHs not associated with instrumental delivery are known to be related with coagulopathy or perinatal head trauma such as falling down on the floor. In our current case, the SGH was developed without any use of instruments during the vaginal delivery of a neonate with CDM, which makes this case deserved as a case report.

It is well known that the risk of obstetric complications is significantly increased in women with DM1, such as preterm birth, polyhydramnios, placenta previa, ectopic pregnancy, postpartum hemorrhage due to atonic uterus, and labor abnormalities of all three stages with consequence of increasing number of operative deliveries²⁾. The mother of current case also suffered from postpartum hemorrhage due to the inadequate uterine contraction. However, those women with DM1 who are not aware of their disease could not be informed of potential complications related with DM1 during the pregnancy and delivery. These obstetric risks could lead

their offspring to develop neurodevelopmental disorders such as cerebral palsy. Moreover, typical neonatal symptoms of CDM such as hypotonia, respiratory distress, and/or feeding difficulties are frequently misunderstood as the sequelae of obstetric and perinatal complications, leading to belated diagnosis of CDM²⁾. Therefore, better awareness of the clinical picture of maternal DM1 could help obstetricians to give information about the potential complications related with DM1 for mother and child to family, providing a chance to bring about better gestational outcome of DM1.

To the best of our knowledge, it is the first report of CDM complicated with huge SGH in unassisted vaginal delivery. Further case reports are needed to understand the relationship between CDM and SGH.

국문초록

모상건막하 혈종은 주로 진공흡인기 혹은 겸자 등을 사용하는 비보조 질식분만 과정에서 발생하는 바, 비보조 질식분만과정에 발생하는 예는 드물다. 또한 선천성 근긴장성 이영양증과 모상건막하 혈종의 동시 발생은 희귀한 것으로 알려져 있다. 저자들은 비보조 질식분만 과정에서 모상건막하 혈종이 발생하였고, 이후 선천성 근긴장성 이영양증으로 진단된 증례를 경험한

바, 이는 선천성 근긴장성 이영양증에서 발생한 비보조 질식분만 과정과 관련된 모상건막하 혈종의 첫 증례인 것으로 판단되어 보고하고자 한다. 본 아동은 임신 기간 중 양수과다증과 태동의 저하를 보였으며, 출생직후 촬영한 뇌컴퓨터단층촬영상 좌측 두정부 및 후두부에 모상건막하 혈종이 발견되었으며 생후 2개월에 모계에서 유전된 선천성 근긴장성 이영양증으로 진단되었다.

References

- 1) Filippova GN, Thienes CP, Penn BH, Cho DH, Hu YJ, Moore JM, et al. CTCF-binding sites flank CTG/CAG repeats and form a methylation-sensitive insulator at the DM1 locus. *Nat Genet* 2001;28:335-43.
- 2) Rudnik-Schoneborn S, Zerres K. Outcome in pregnancies complicated by myotonic dystrophy: a study of 31 patients and review of the literature. *Eur J Obstet Gynecol* 2004;114:44-53.
- 3) Uchil D, Arulkumaran S. Neonatal subgaleal hemorrhage and its relationship to delivery by vacuum extraction. *Obstet Gynecol Surv* 2003;58:687-93.
- 4) Kuo H, Hsiao K, Chen C, Hsieh Y, Huang C. Brain magnetic resonance image changes in a family with congenital and classic myotonic dystrophy. *Brain Dev* 2005;27:291-6.
- 5) Liao YH, Sue WC, Jang DR, Soong BW, Peng S, Chou GS. Congenital myotonic dystrophy: report of one case. *Acta Paediatr Taiwan* 2003;44:155-7.